

## Reduction mammoplasty. What radiologists should know.

**Poster No.:** C-1558  
**Congress:** ECR 2016  
**Type:** Educational Exhibit  
**Authors:** S. Plaza Loma<sup>1</sup>, Y. Rodríguez de Diego<sup>1</sup>, M. E. Villacastín Ruiz<sup>1</sup>,  
R. Pintado Garrido<sup>1</sup>, A. Ginés Santiago<sup>2</sup>, M. Hernandez Herrero<sup>1</sup>;  
<sup>1</sup>Valladolid/ES, <sup>2</sup>Valladolid/ES  
**Keywords:** Breast, Mammography, Ultrasound, MR, Surgery, Image registration  
**DOI:** 10.1594/ecr2016/C-1558

Any information contained in this pdf file is automatically generated from digital material submitted to EPOS by third parties in the form of scientific presentations. References to any names, marks, products, or services of third parties or hypertext links to third-party sites or information are provided solely as a convenience to you and do not in any way constitute or imply ECR's endorsement, sponsorship or recommendation of the third party, information, product or service. ECR is not responsible for the content of these pages and does not make any representations regarding the content or accuracy of material in this file.

As per copyright regulations, any unauthorised use of the material or parts thereof as well as commercial reproduction or multiple distribution by any traditional or electronically based reproduction/publication method is strictly prohibited.

You agree to defend, indemnify, and hold ECR harmless from and against any and all claims, damages, costs, and expenses, including attorneys' fees, arising from or related to your use of these pages.

Please note: Links to movies, ppt slideshows and any other multimedia files are not available in the pdf version of presentations.

[www.myESR.org](http://www.myESR.org)

# Learning objectives

To review the imaging features of reduction mammoplasty and to identify normal postoperative findings and the most common associated complications.

## Background

Breast reduction is an extremely common procedure with around 100,000 cases performed annually in the United States. Classically breast reduction is indicated for women with macromastia, who often complain of associated back, neck, and shoulder pain. These women may also show chronic inframmary intertrigo and excoriations from the bra straps.

Other reasons women desire the procedure are purely cosmetic and it is also often employed for symmetry of the contralateral breast following mastectomy and breast reconstruction.

### ***Breast reduction techniques***

The goal of breast reduction, or reduction mammoplasty, is to remove excess fat, glandular tissue, and skin to achieve the patient's desired breast size.

There is a wide variety of breast reduction surgical techniques. The choice depends on the extent of ptosis, breast size and shape, estimated resection volume and the surgeon's experience.

Reduction mammoplasty technique has two components: skin incision pattern and volume reduction or glandular resection pattern.

With regard to the *pattern of skin incision* (Fig. 1 on page 3), in the traditional Wise pattern, or inverted T scar or anchor scar, a key-hole incision leaves a periareolar scar, a vertical scar in the midline of the inferior mammary hemisphere, and a curvilinear scar along the inframammary fold.

With the purpose of shortening and hiding the scar, newer vertical scar techniques feature a vertical incision alone leaving only a periareolar scar and a vertical scar along

the midline of the lower hemisphere of the breast. The resulting scar has a lollipop-shaped appearance. Use of the vertical incision decreases scarring and distortion of the inframammary fold.

Finally, periareolar technique is used in small to moderate reductions.

With regard to the *pattern of glandular resection* (Fig. 2 on page 4), the different techniques used in breast reduction are identified by the segment of the breast that is left unresected, which becomes the structure and support of the new breast. This "pedicle" also contains the vascular supply of the breast mound, including the nipple-areola complex. The pedicle can be derived from tissue in any direction relative to the NAC. Various techniques include superior, superomedial, medial, inferior, lateral and central pedicles.

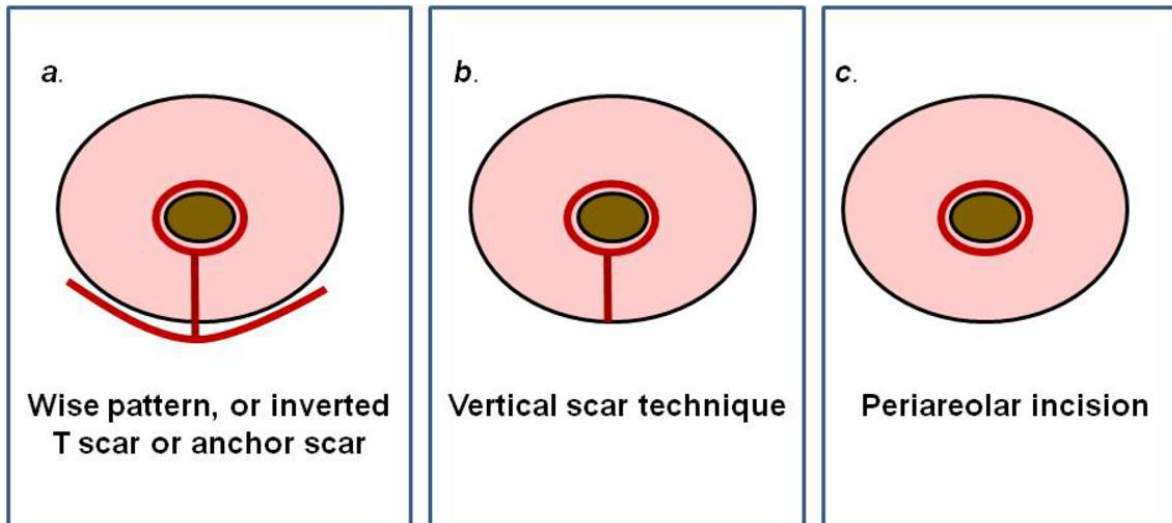
Wise skin incision pattern with inferior pedicle technique (Fig. 3 on page 5) has become the standard to which all other variations are compared and is the most commonly performed breast reduction procedure. This technique utilizes a key-hole incision and an inferior pedicle for blood supply to the nipple areola complex. Excess breast tissue is removed medially, laterally, and superiorly. When the incisions are closed the patient is left with a classic anchor incision. This technique does have its limitations and resulting breasts tend to have long scars, long term boxy shape and lack of breast projection. It also has advantages including good circulation, good sensation and possibility of breast feeding.

The superior dermoglandular pedicle method (which involves the resection of the medial, lateral, and inferior portions of the breast parenchyma) is the pattern of resection used in the Lejour technique (Fig. 3 on page 5). The vertical scar incision pattern is the skin incision that is used and the NAC and pedicle are repositioned superiorly as breast tissue is removed. Suture suspension of the pedicle to pectoralis muscle fascia and total breast liposuction are also performed. Its advantages are that it preserves the area that is less prone to undergo further ptosis secondary to downward pulling action of gravity, as well as maintaining fullness in the upper pole of the breast while allowing for small, medium, and large resections.

**Images for this section:**

# REDUCTION MAMMOPLASTY

## Pattern of skin incision...

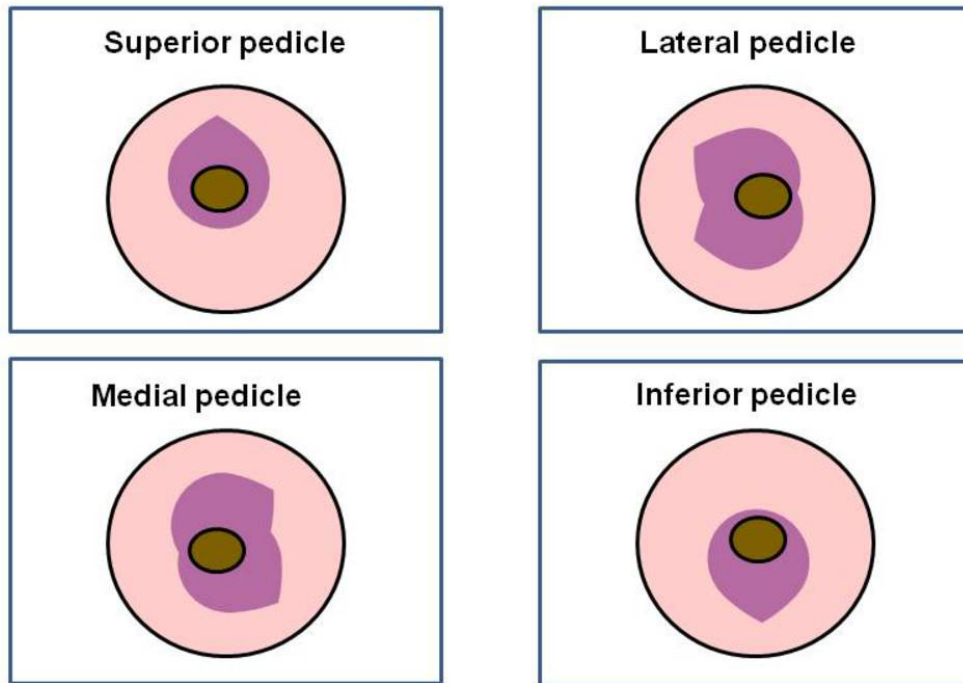


**Fig. 1:** Pattern of skin incision. (a) Wise pattern, or inverted T scar or anchor scar, leaves a periareolar scar, a vertical scar in the midline of the inferior mammary and a curvilinear scar along the inframammary fold. (b) Vertical scar techniques leave a periareolar scar and a vertical scar along the midline of the lower hemisphere of the breast. The resulting scar has a lollipop-shaped appearance. (c) Periareolar technique leaves a periareolar scar.

© - Valladolid/ES

# REDUCTION MAMMOPLASTY

## Pattern of glandular resection

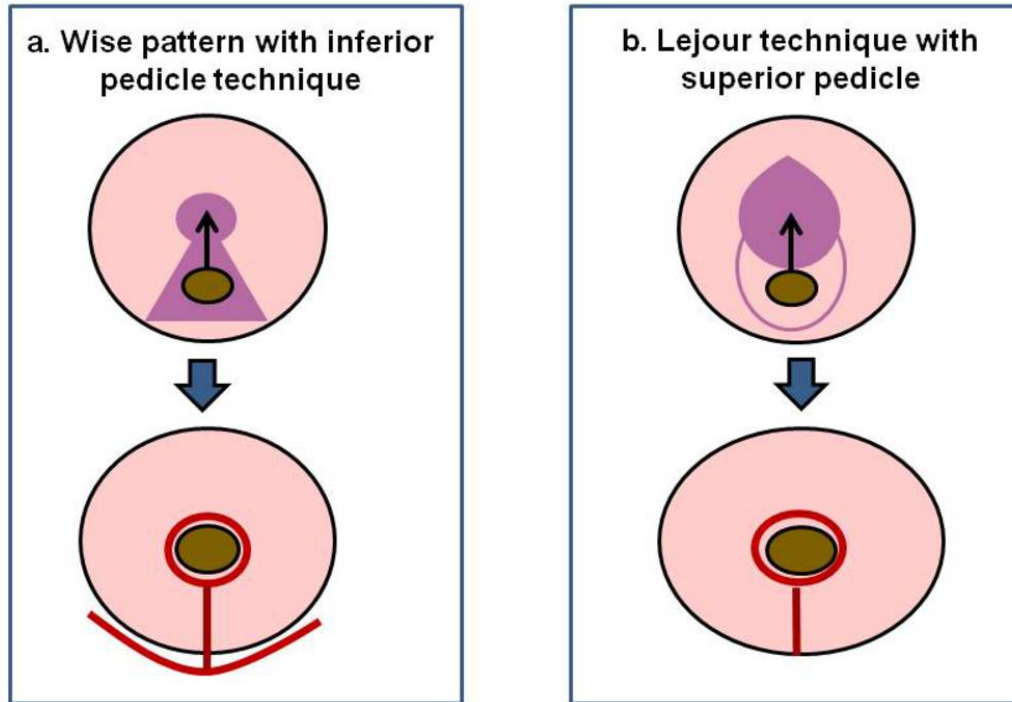


**Fig. 2:** Pattern of glandular resection. The different techniques used in breast reduction are identified by the segment of the breast that is left unresected, which becomes the structure and support of the new breast. This "pedicle" can be derived from tissue in any direction relative to the NAC. Various techniques include superior, superomedial, medial, inferior, lateral and central pedicles.

© - Valladolid/ES

# REDUCTION MAMMOPLASTY

## Reduction mammoplasty techniques



**Fig. 3:** Reduction mammoplasty techniques. (a) Wise skin incision pattern with inferior pedicle technique. This technique utilizes a key-hole incision and an inferior pedicle for blood supply to the nipple areola complex. When the incisions are closed the patient is left with a classic anchor incision or inverted T scar. (b) Lejour technique. The vertical scar incision pattern is the skin incision that is used and the NAC and pedicle are repositioned superiorly as breast tissue is removed.

© - Valladolid/ES

## Findings and procedure details

### *Normal postoperative findings*

Imaging findings in postoperative imaging demonstrate abnormalities associated with skin-incision sites, repositioning of the NAC, and parenchymal redistribution and can be seen at mammography and MR imaging.

Most common mammographic findings after reduction mammoplasty include parenchymal redistribution, elevation of the nipple, areolar thickening and periareolar dermal calcifications and skin thickening from scar tissue. Another characteristic finding is a retroareolar fibrotic band from the transposed flap, which can be seen extending to the repositioned NAC, parallel to the skin contour. It likely represents scarring associated with the vascular pedicle.

Parenchymal redistribution occurs in 90% of cases and can be seen at mammography and MR imaging. Because multiple techniques can be used to reshape the parenchyma the pedicle can be derived from tissue in any direction relative to the NAC (Fig. 4 on page 9).

Typical mammographic findings in the traditional inverted T scar or Wise pattern (Fig. 5 on page 10) include a downward shift of the ductal and fibroglandular tissue, as seen on the mediolateral view, and linear scar between the nipple and inframammary fold that accounts for the frequent finding of skin thickening or keloids and dermal calcifications along the inframammary fold.

Assymmetric densities due to tissue removal and scarring are present in approximately half the patients. It is also frequent to find benign calcifications and the development of fat necrosis.

Imaging features in postoperative MRI (Fig. 6 on page 11) also demonstrate abnormalities associated with skin-incision sites, repositioning of the NAC, and parenchymal redistribution.

### *Postoperative complications*

With surgical techniques come complications, some of which may mimic malignancy clinically and radiologically. In breast mammoplasty, 9.5% patients have biopsies for

suspicious imaging findings which were benign on pathology. One of the most common breast reduction complications is the development of fat necrosis.

### Fat necrosis

Fat necrosis appearance can vary from benign to highly suspicious and can clinically and radiologically mimic breast cancer.

The imaging features of fat necrosis are variable, depending on its stage and degree of fibrosis. The initial change is disruption of fat cells where vacuoles with the remnants of necrotic fat cells are formed. They then become surrounded by acute inflammatory cells. Fibrosis develops during the reparative-late phase peripherally enclosing an area of necrotic fat and cellular debris.

Most cases are clinically occult but sometimes fat necrosis may mimic carcinoma by presenting as a palpable painless mass or with associated findings such as nipple retraction.

The most common fat necrosis mammographic findings are dystrophic calcifications, followed by radiolucent oil cysts with or without rim or eggshell calcification ([Fig. 7](#) on page 12). The calcification of fat necrosis is typically peripheral with a stippled curvilinear appearance creating the appearance of lucent "bubbles" or low density centres in the breast parenchyma. With time, it becomes more defined and well-circumscribed giving rise to an oil cyst ([Fig. 8](#) on page 13).

Note that fat necrosis of the breast can change with time with progressive calcification so comparison with previous imaging is essential. Also, the changes can often be seen and correlated with the position of surgical scarring on the breast.

Fat necrosis can also present as thickening and deformity of the skin and subcutaneous tissue, focal mass ([Fig. 9](#) on page 14, [Fig. 10](#) on page 15), ill-defined spiculated mass and clustered pleomorphic microcalcifications which can mimic malignancy.

Sonographic features ([Fig. 11](#) on page 16) also vary, and may appear as cystic or solid masses. Ultrasound findings include anechoic cyst with posterior acoustic enhancement, cystic mass with internal echoes, complex mass with mural nodules, ill-defined echogenic area, hypoechoic mass with posterior acoustic shadowing, and solid masses. Solid masses can have well-circumscribed or ill-defined margins, and are often associated with distortion of the breast parenchyma. The features depict the histological evolution



of fat necrosis. Ultrasound of fat necrosis should always be interpreted in the context of mammographic findings

MR imaging is the most appropriate imaging modality for characterizing fat necrosis that has an atypical appearance on images obtained with other modalities. On MRI, fat necrosis appearance varies widely with the amount of fat and the extent of inflammation and fibrosis.

A mass that exhibits the signal intensity of fat over all and has a low-signal-intensity peripheral fibrous rim is a characteristic finding of fat necrosis (Fig. 12 on page 17). On MRI, fat necrosis can be characterized by a round or irregular mass with central high-signal intensity on non fat-suppressed unenhanced T1W images and high signal on T2W images. On fat-suppressed T1-weighted images, the loculated fat will show suppression of signal similar to the adjacent fat.

Fat necrosis can enhance after the injection of IV contrast material. Enhancement, when present, is variable but typically peripheral and early. The enhancing areas correspond to developing fibrosis and inflammatory cell infiltration, and the non-enhancing, usually central areas correspond to necrotic fat.

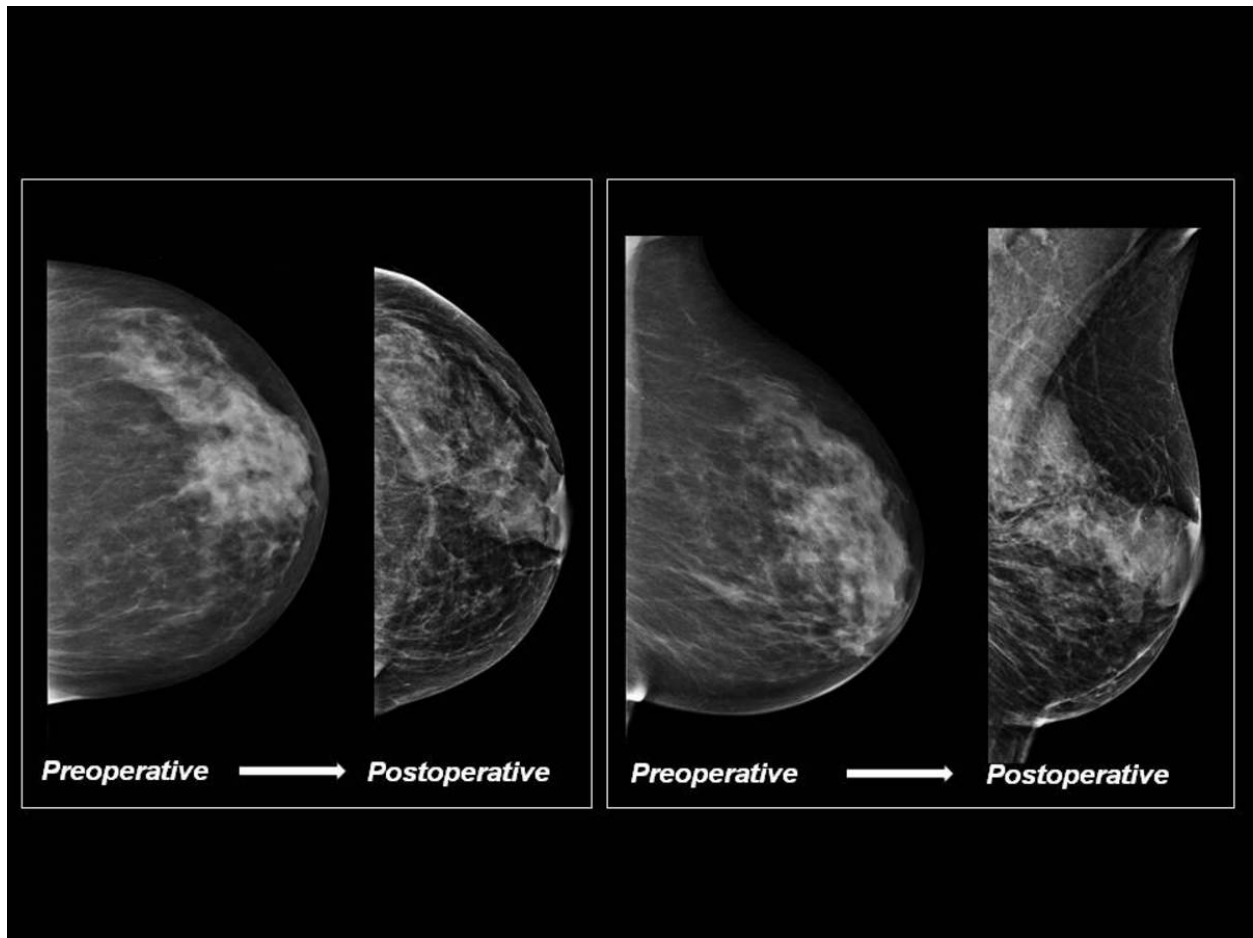
Fat necrosis may also appear as an enhancing focus, or clumped non-mass-like enhancement when it contains a minimal amount of fat. The specificity of MRI for fat necrosis can be further improved by correlation with mammography to detect oil cyst or coarse microcalcifications.

### ***Breast cancer***

All patients over 40 years of age should have a preoperative mammogram to detect any disorder of the breast prior to surgery.

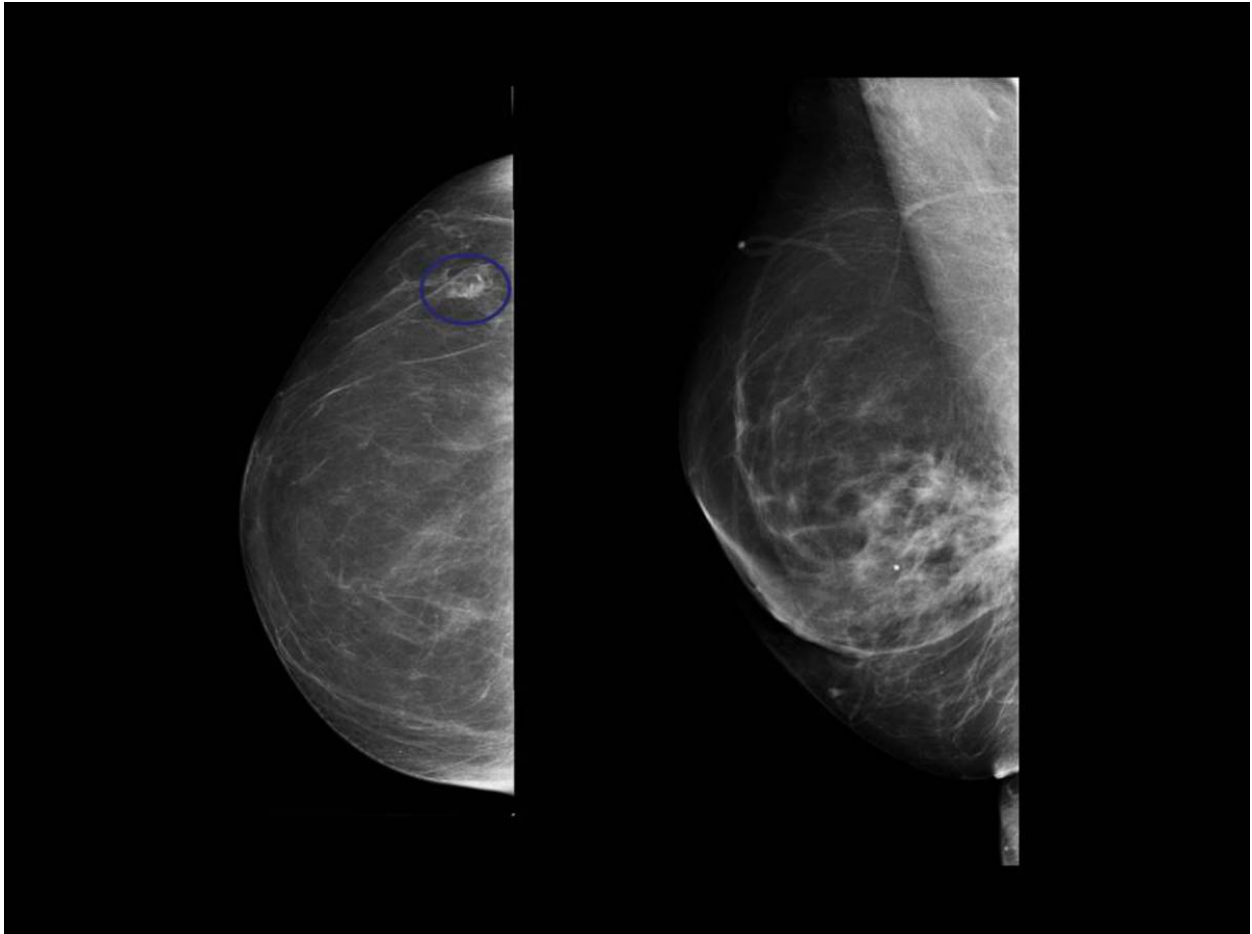
Approximately 6 months after surgery, a new baseline mammogram should be obtained for future reference, because redistribution of glandular tissue and scarring make comparison with previous images difficult. Any new findings from the baseline examination, such as a developing density, mass, or calcifications, require a thorough evaluation, including possible tissue sampling. Fig. 13 on page 18, Fig. 14 on page 19, Fig. 15 on page 20, Fig. 16 on page 21.

**Images for this section:**



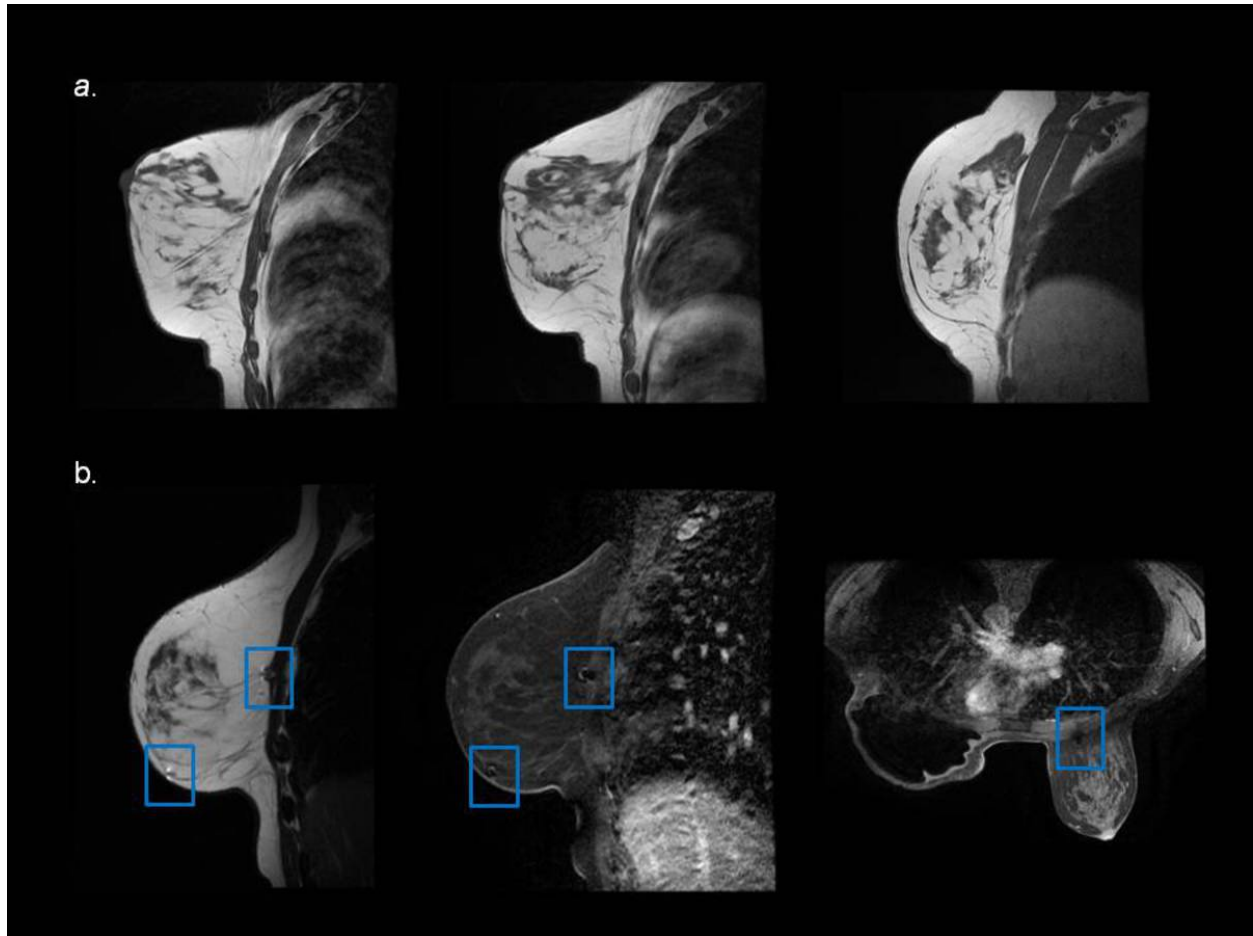
**Fig. 4:** Normal postoperative findings (Lejour technique). Preoperative and postoperative mammograms are shown for comparison. Mammographic findings after reduction mammoplasty include parenchymal redistribution, elevation of the nipple, areolar thickening and inferior vertically oriented skin thickening from scar tissue.

© - Valladolid/ES



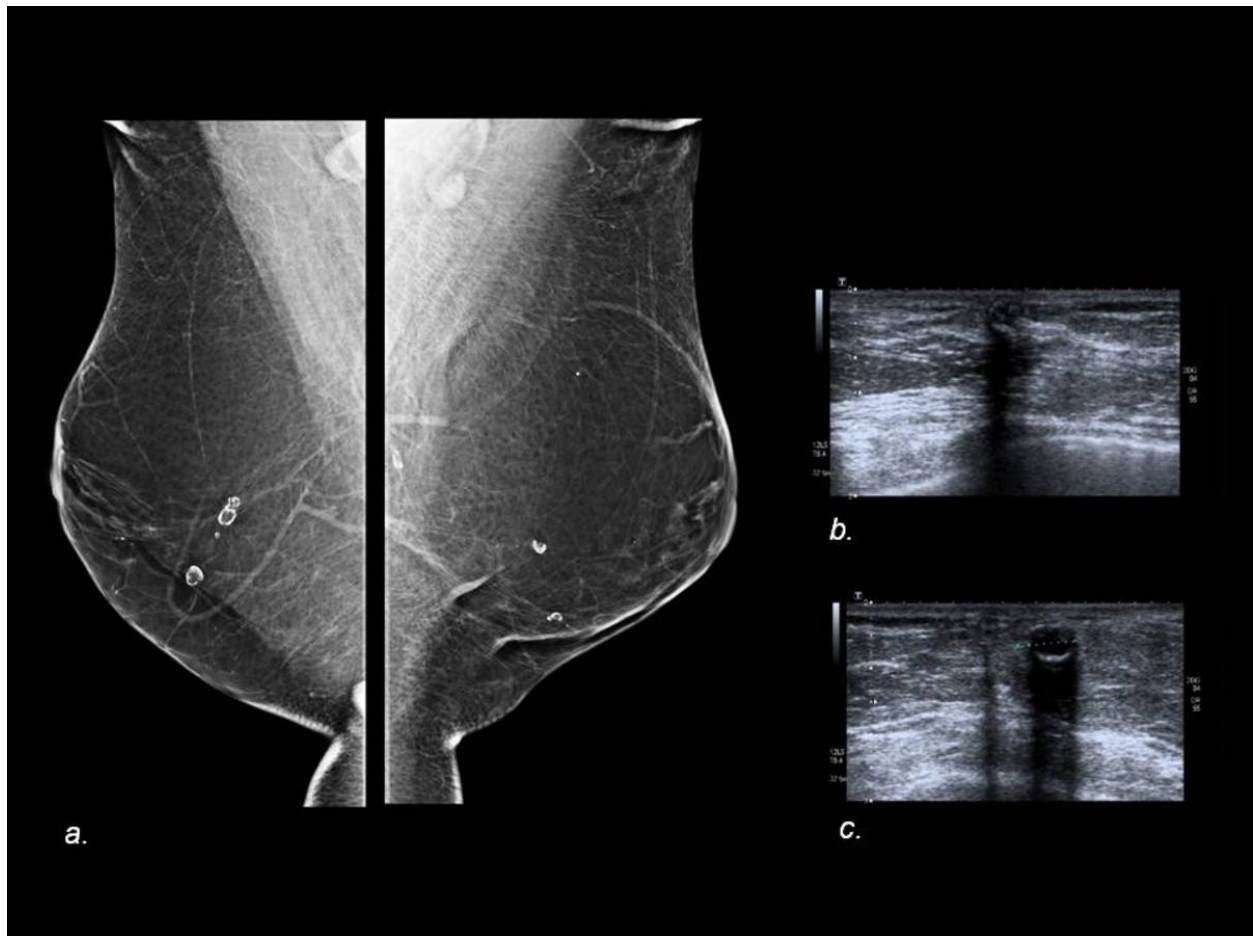
**Fig. 5:** Normal postoperative findings (Wise pattern). Mammogram of the right breast shows a downward shift of the ductal and fibroglandular tissue and linear scar between the nipple and inframammary fold, as seen on the mediolateral view. Assymmetric density (circle) with lucent area and curvilinear calcifications is seen in outer quadrant in CC view and is related to fat necrosis.

© - Valladolid/ES



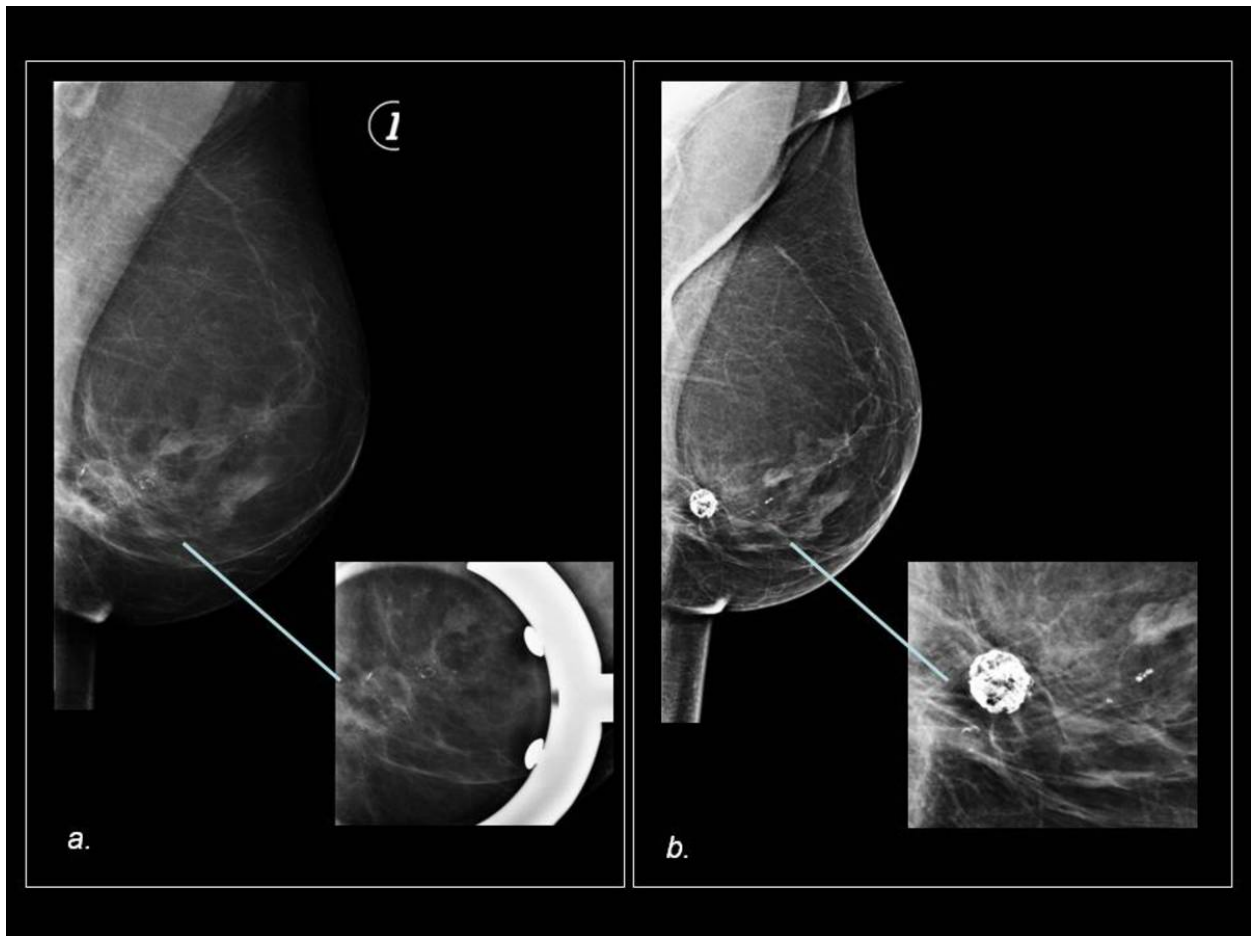
**Fig. 6:** Normal MRI postoperative findings after reduction mammoplasty. (a) Sagittal T2 -weighted MR images show elevation of the nipple, parenchymal redistribution and inferior skin thickening from scar tissue. (b) Left breast reconstruction with implant and right breast reduction mammoplasty. T1 weighted and fat-suppressed images show susceptibility artifacts (blue box).

© - Valladolid/ES



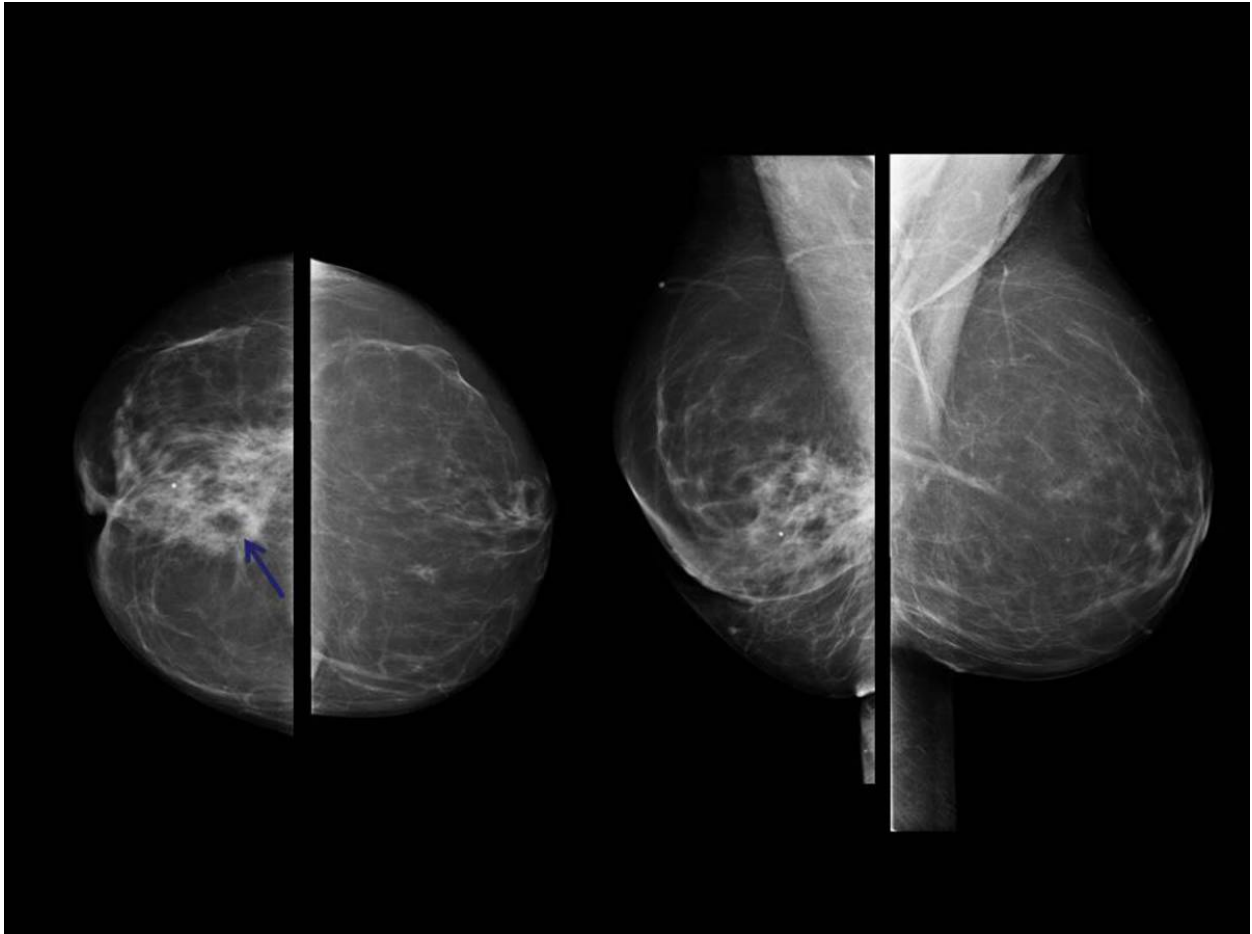
**Fig. 7:** 37-year-old woman with history of reduction mammoplasty . Mediolateral oblique mammograms (a) reveal focal well-circumscribed radiolucencies with rim calcification. Gray-scale sonogram (b,c) reveals cystic masses with internal echoes and rim calcification. Findings are consistent with benign oil cyst.

© - Valladolid/ES



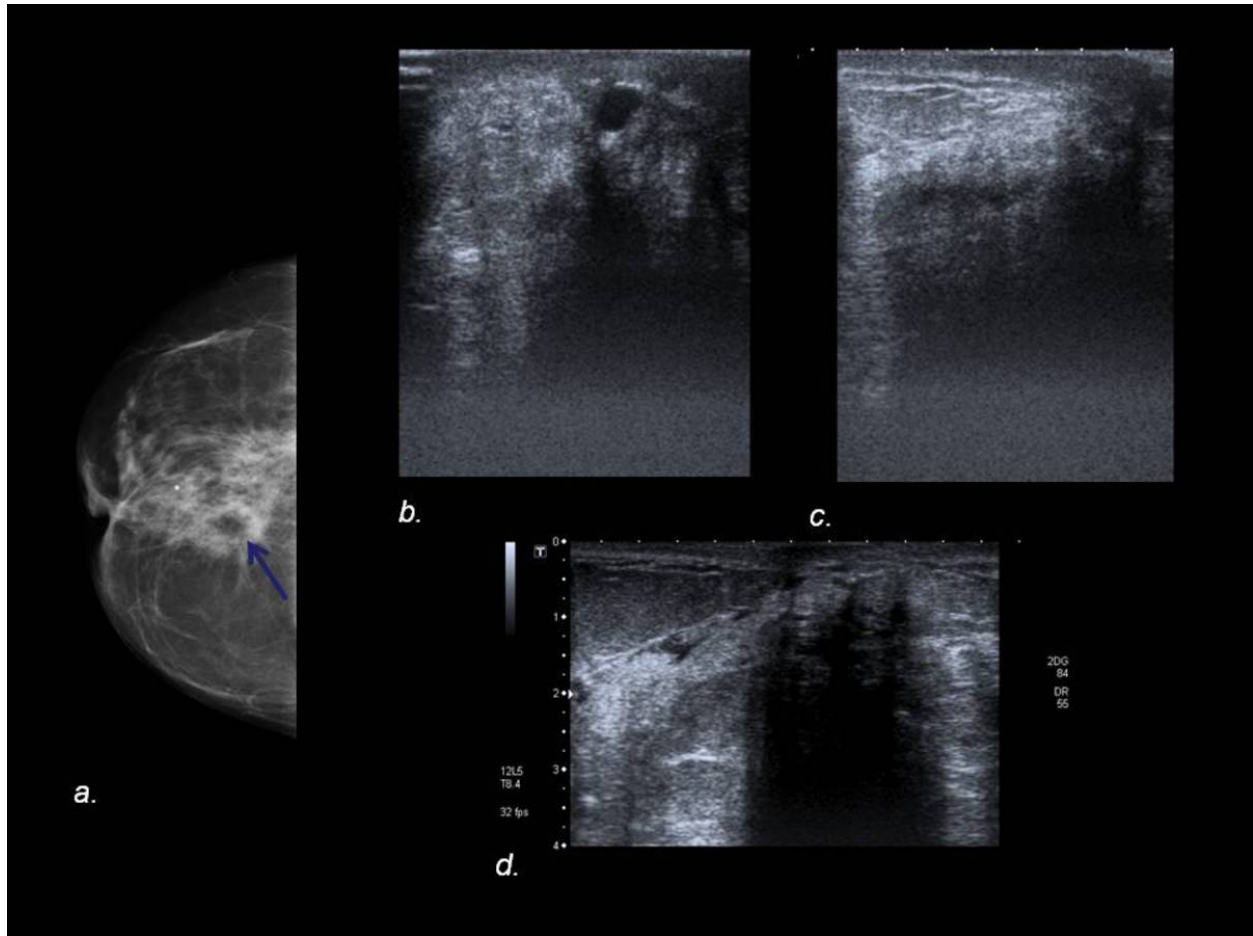
**Fig. 8:** 58-year-old woman with history of reduction mammoplasty (Wise pattern). Mammogram shows downward shift of the ductal and fibroglandular tissue and linear scar between the nipple and inframmary fold, as seen on the mediolateral view. In (a) lucent areas and stippled curvilinear and peripheral calcifications are shown in the inferior quadrant. Mammogram obtained 4 years after (b) shows coarse calcifications and calcified lipid cyst compatible with progressing fat necrosis.

© - Valladolid/ES



**Fig. 9:** 57-year-old woman with history of reduction mammoplasty who presented with palpable retroareolar right mass and nipple retraction. Mammogram reveals a right retroareolar focal asymmetry with radiolucency density within it (arrow). Parenchymal redistribution and skin thickening in the inferior area of the breast can be seen.

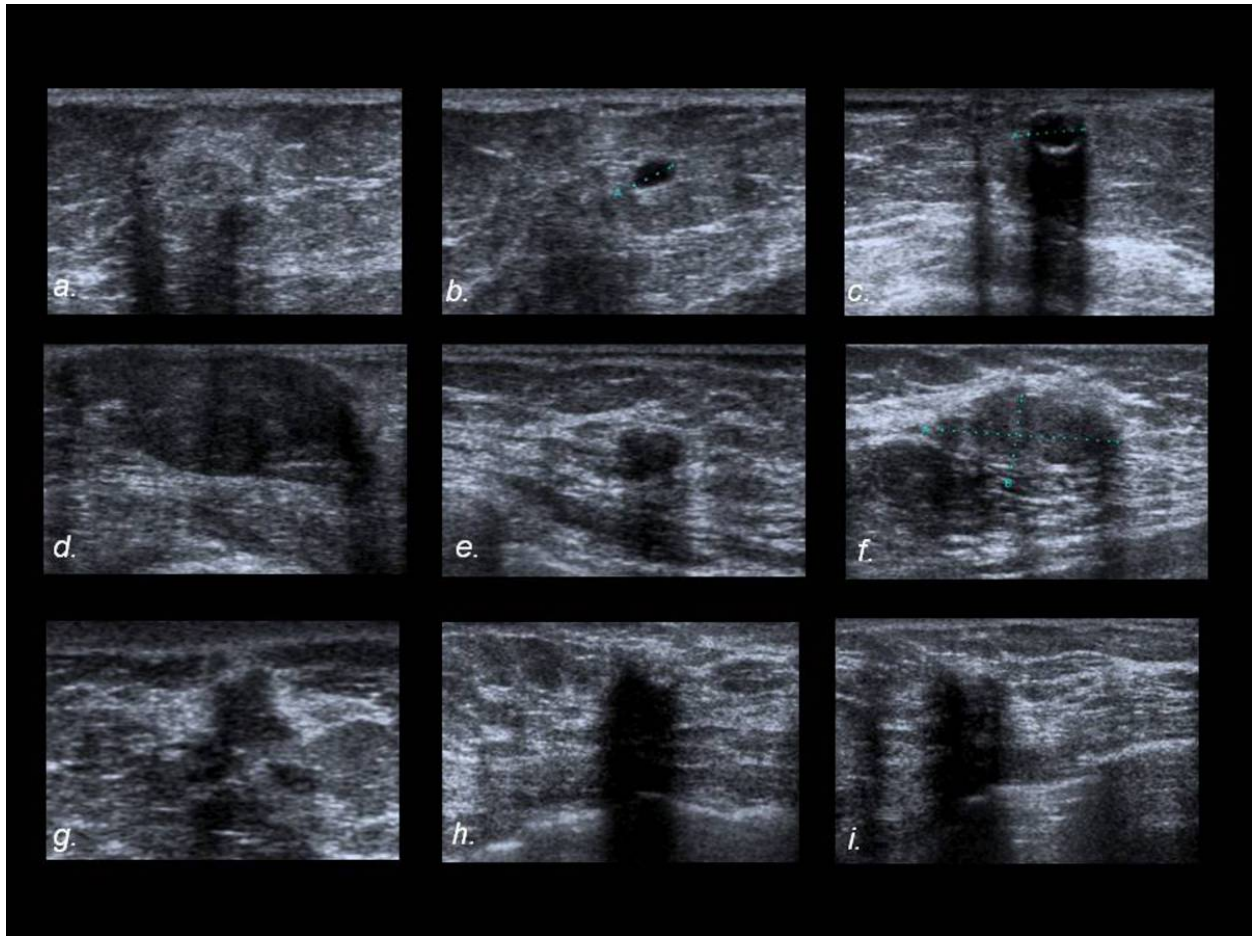
© - Valladolid/ES



**Fig. 10:** Mammogram (a) reveals a right retroareolar focal asymmetry with radiolucent density within it (arrow). US images (b,c,d) show an ill-defined echogenic area with a cystic mass within it and an hypoechoic area with posterior acoustic shadowing. US-guided biopsy showed fat necrosis.

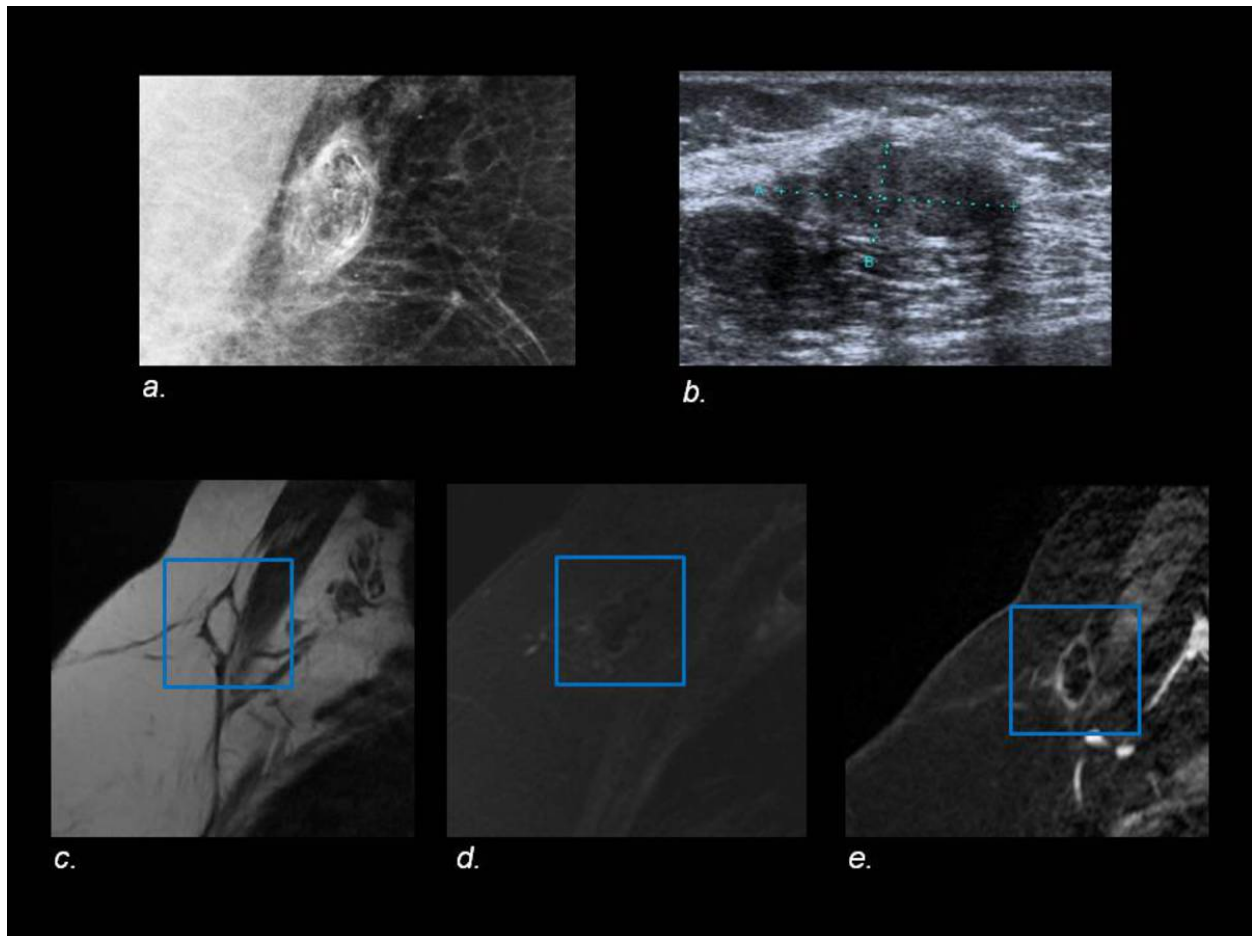
© - Valladolid/ES





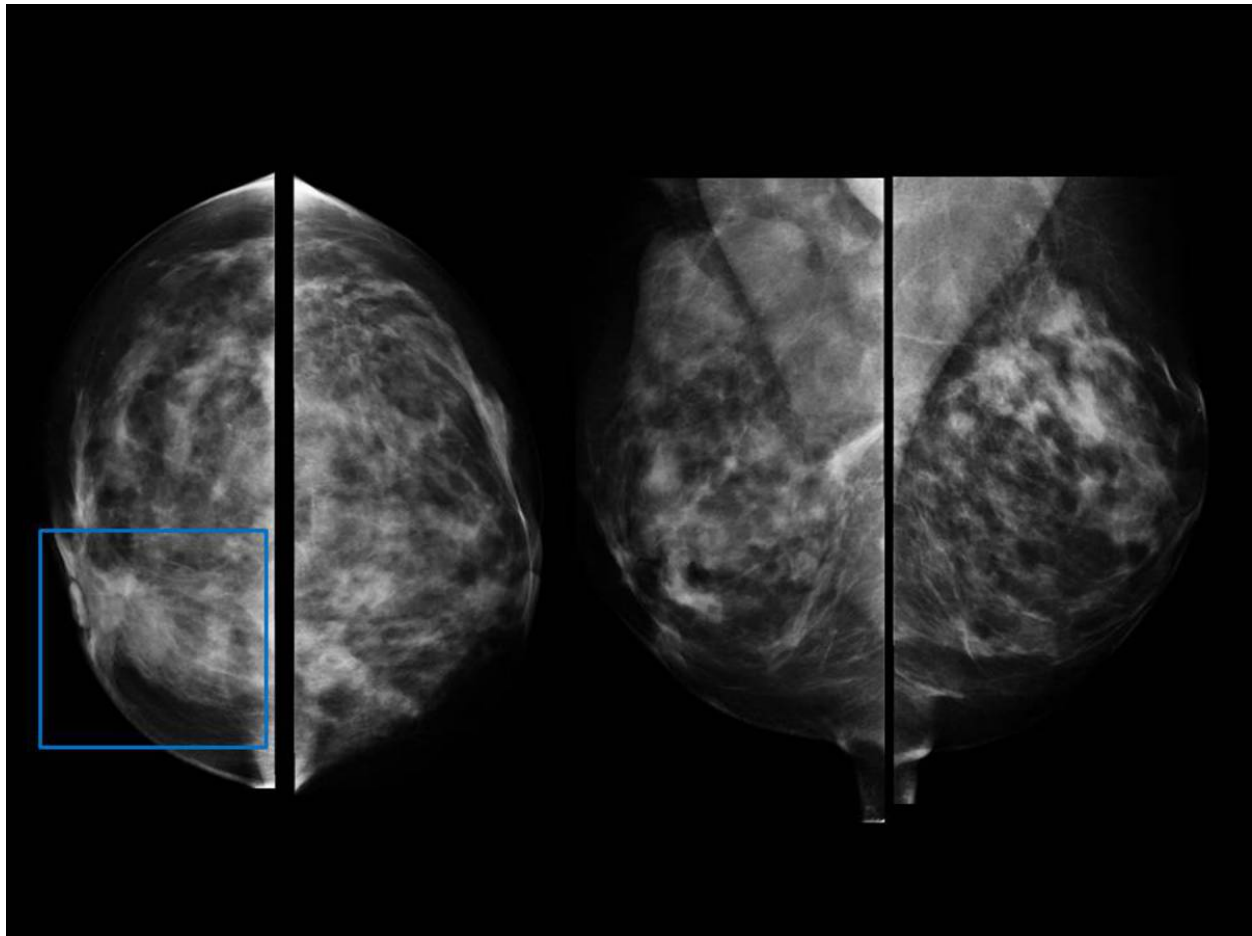
**Fig. 11:** Sonographic imaging features of fat necrosis including an ill-defined echogenic area with a cystic mass within it (a,b), cystic mass with rim calcification (c), solid masses with well-circumscribed margins (d,e,f) and ill-defined margins (g,h,i).

© - Valladolid/ES



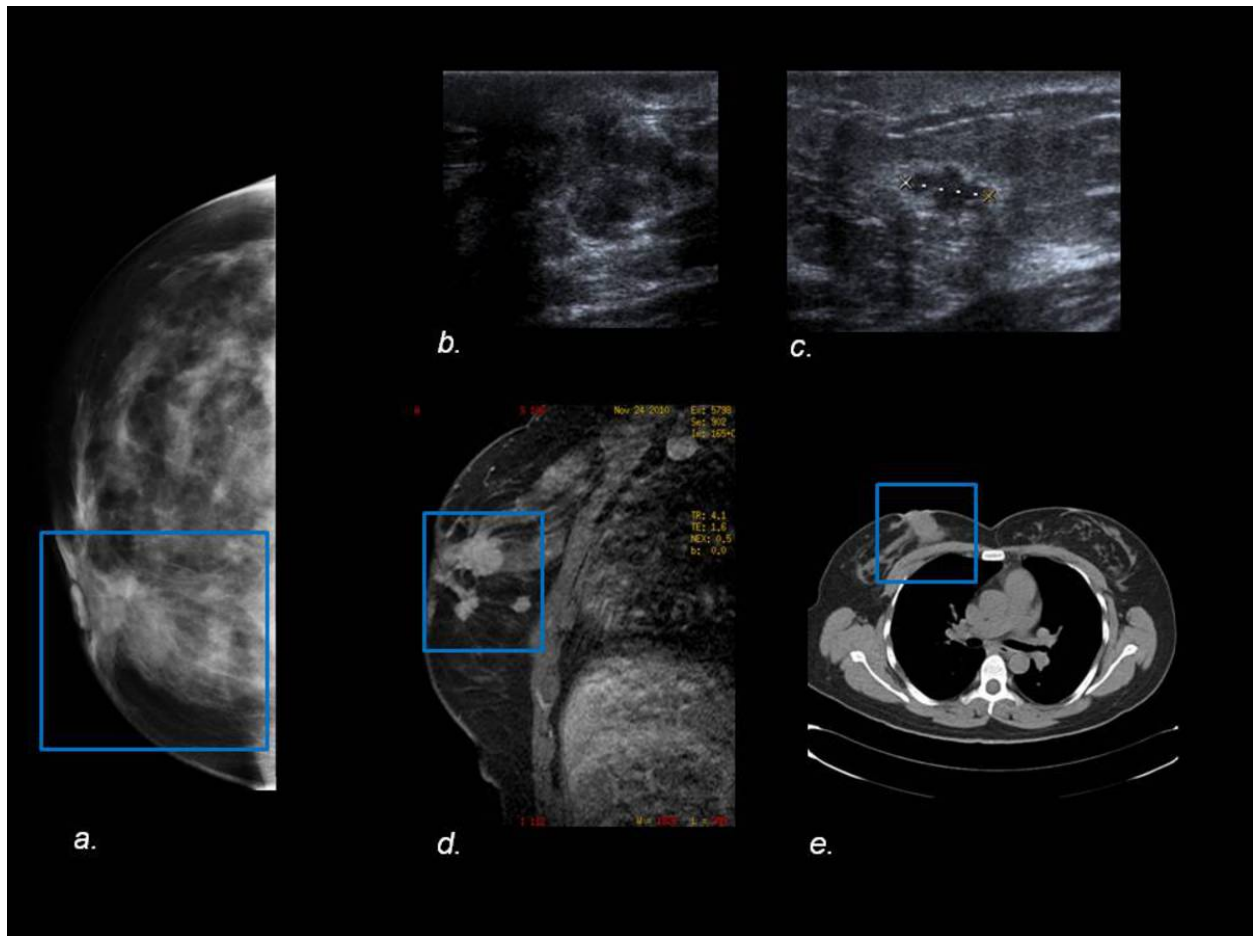
**Fig. 12:** Mediolateral oblique mammogram (a) shows a mass with lucent areas and stippled curvilinear and peripheral calcifications. US image (b) shows a well-margined, solid hypoechoic mass. Sagittal T2-weighted MR image (c) shows a mass with central high-signal intensity, similar to fat elsewhere in the breast. On fat-suppressed image (d), the loculated fat shows suppression and on gadolinium-enhanced subtraction image (e) a fat-containing mass surrounded by an enhancing fibrous rim can be seen.

© - Valladolid/ES



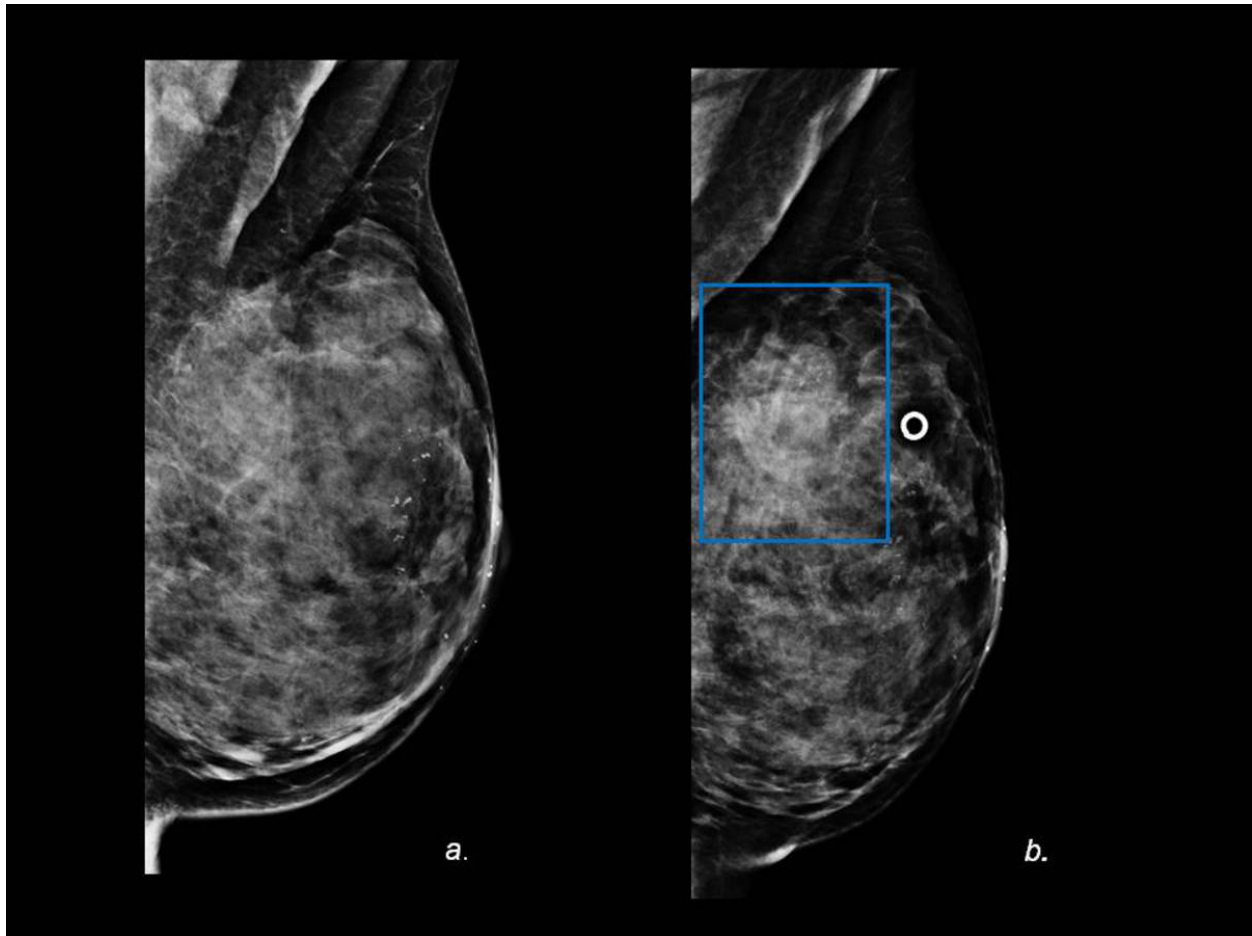
**Fig. 13:** 49-year-old woman with history of reduction mammoplasty who presented with a palpable retroareolar breast mass. Mammogram shows a retroareolar ill-defined mass, best seen on CC view (blue box). Parenchymal redistribution and nipple elevation after reduction mammoplasty can be seen.

© - Valladolid/ES



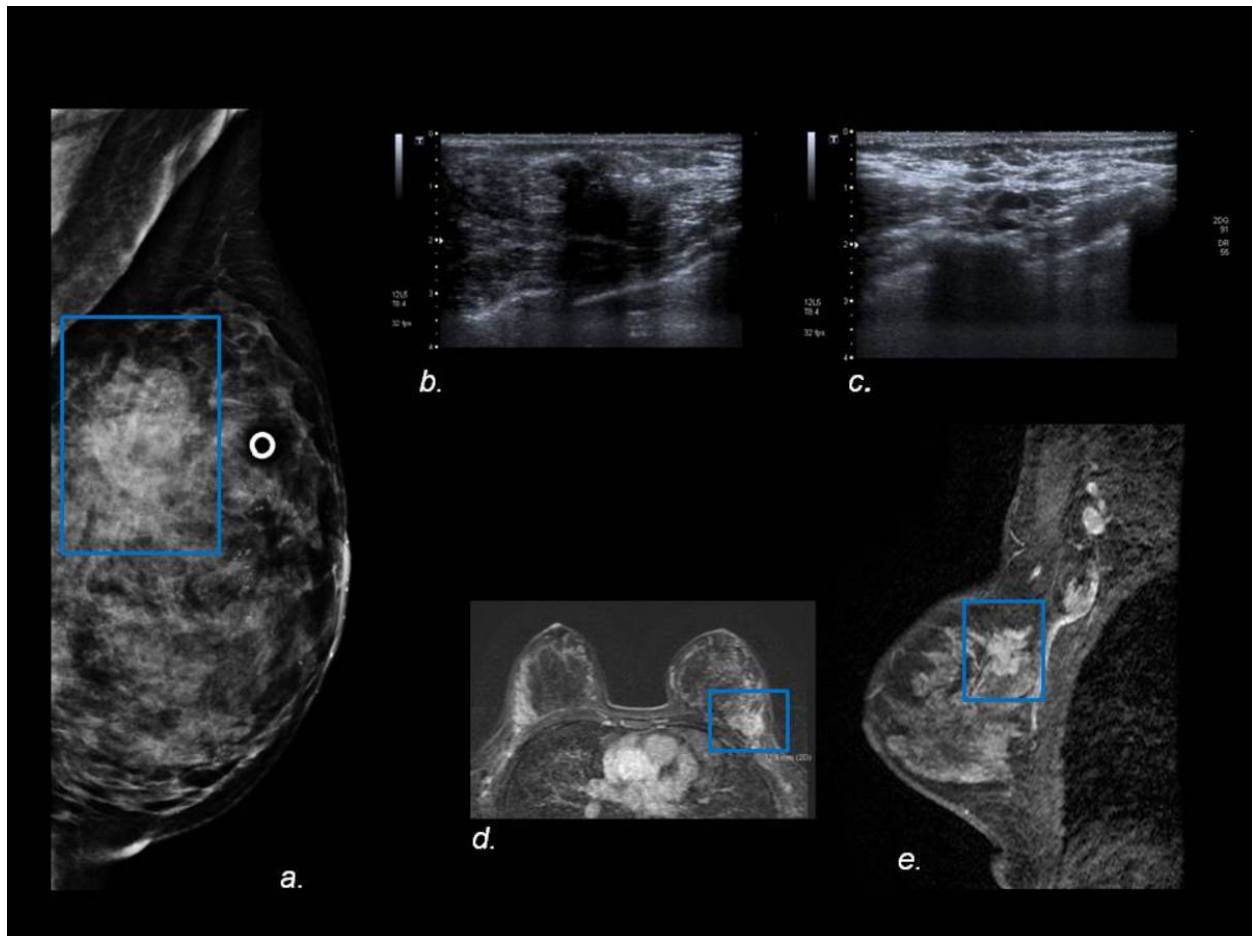
**Fig. 14:** (a)CC view shows a retroareolar ill-defined mass (blue box). Sonogram (b,c) shows an irregular retroareolar hypoechoic mass (b) and two additional irregular nodules (c) suspicious for malignancy (one shown). Contrast-enhanced T1-weighted MR image (d) shows enhancing irregular masses in the right breast (blue box). On CT (e) retroareolar mass is also shown (blue box). On surgical biopsy multicentric invasive ductal carcinoma was found.

© - Valladolid/ES



**Fig. 15:** (a) Mediolateral oblique mammogram of the left breast in a 41-year-old woman after reduction mammoplasty shows periareolar dermal calcifications and areolar thickening related to the repositioned NAC and skin thickening in the inferior area of the central breast. (b) 2 years after surgery she presented with new palpable mass in the upper outer quadrant (skin marker). Mediolateral oblique mammogram show an ill-defined mass (blue box) that was not present on previous mammograms.

© - Valladolid/ES



**Fig. 16:** (a)Mediolateral oblique mammogram of the left breast shows an ill-defined mass (blue box) that was not present on previous mammograms. US image (b,c) shows a solid hypoechoic mass with ill-defined margins (b) and axillary node with cortical thickening (c). Contrast-enhanced T1-weighted MR image (d,e) shows enhancing spiculated mass (blue box)in upper outer portion of left breast. Abnormal axillary nodes are also shown. US-guided biopsy showed the mass to be a lobular invasive carcinoma.

© - Valladolid/ES

## Conclusion

Knowledge of the imaging features of breast surgical techniques and their expected common postoperative complications may be helpful to differentiate between benign and malignant entities and to avoid false-positive imaging findings and unnecessary biopsies in these patients.

## Personal information

## References

- Roberts JM, Clark CJ, Campbell MJ, et al. Incidence of abnormal mammograms after reduction mammoplasty: implications for oncoplastic closure. *Am J Surg* 2011;201(5):611-614.
- Rubin JP, Coon D, Zuley M, et al. Mammographic changes after fat transfer to the breast compared with changes after breast reduction: a blinded study. *Plast Reconstr Surg* 2012;129(5):1029-1038.
- Danikas D, Theodorou SJ, Kokkalis G, Vasiou K, et al. Mammographic findings following reduction mammoplasty. *Aesthetic Plast Surg* 2001;25(4):283-285.
- Margolis NE, Morley C, Philip Lotfi P, et al. Update on Imaging of the Postsurgical Breast. *RadioGraphics* 2014 34:3, 642-660.