

Effectiveness of using Poly Lactide and Caprolactone Acid with Hyaluronic Acid Material

Nikishin DV, Sulamanidze GM, Kajaia AA

Limited Liability Company APTOS, V. Orbeliani str 18, 0105, Tbilisi, Georgia.

Abstract

In recent years, minimally invasive procedures attract a significant interest. One of the most common methods for lifting of soft facial tissues is a thread lifting. Wide variety of threads are presented on the market, made from various materials and with various configurations.

Objective: This article describes comparison of two different tread materials in accordance with therapeutic effectiveness, short recovery period and safety.

Methods: Study was conducted on the 4-month-old pigs, with weight of 40 kg

Results: The results of histological studies showed an effectiveness of use of PLA and PLA HA 1% materials, unlike of control group. However, unlike PLA material, PLA HA 1% material had advantages. First, it has better bioinert characteristics, which was manifested in the absence of local reaction on implant.

Conclusion: In accordance with study results PLA HA 1% material had an advantage over PLA material, providing collagenesis and elastin fibers formation which ensures more manifested "rejuvenating" effect of the skin at early stages of thread implantation.

Keywords: Skin Ageing; Thread Lifting; Poly-l-lactic acid; Polycaprolactone; Hyaluronic acid; Neocollagenesis.

Introduction

Modern aesthetic medicine offers number of options how to solve an ageing problem. In recent years, minimally invasive procedures attract a significant interest.

One of the most common methods for lifting of soft facial tissues currently is a thread lifting. Wide variety of threads for lifting are presented on the market, made from various materials and with various configurations, but they have some negative characteristics to a greater or lesser extent. This may include delayed terms of therapeutic impact, insufficient clinical effect, which is manifested in a low production of collagen and elastin in a skin and subcutaneous fatty cellular tissues, short lifetime, and patients' complaints on discomfort, which is felt in the area of threads insertion.

For elimination of negative consequences, the company conducts active development and improvement of threads, in terms of composition, as well as design, which minimize negative consequences after implantation.

In relation to this, in this work we intended to experimentally compare the effectiveness of use of threads developed by us, based on blend of poly-l-lactic acid with polycaprolactone; poly-l-lactic acid with polycaprolactone and hyaluronic acid (PLA and PLA HA 1%).

Materials and methods

Experimental study was conducted on the 4-month-old pigs, with weight of 40 kg (at the start of the experiment). Thread insertion have been conducted with anesthesia – inhalation and intravenous narcosis.

Access from left: 5 puncture points. Implantation of threads PLA HA 1% 5 pcs. Needle's direction: perpendicular to right paravertebral line from the boundary of spinal erector muscle in subcutaneous cellular tissue in thoracoabdominal direction.

Access from right: 5 puncture points (according to scheme). Implantation of threads PLA 5 pcs. Needle's direction: perpendicular to right paravertebral line from the boundary of spinal erector muscle in subcutaneous cellular tissue in thoracoabdominal direction. Access points were closed by aseptic stickers. Surgery was performed without implication.

After the implantation of threads, skin sampling was performed with subcutaneous cellular tissue for histological study (3 fragments on each time of conclusion-control, PLA, PLA HA 1%), for the following dates of implantation: 14 days, 30 days, 60 days, 90 days, 1 year.

Tissue fragments were fixed in neutral 7% formalin, underwent through graded series of alcohol with increasing concentration and were embedded in wax. Wax section with thickness of 5-7 mm were stained: with hematoxylin and eosin; according to Weigert-Van Gieson method; stain Sirius Red. Using a microscope with digital photo adapter Sony with resolution of 12 megapixels, 5 photos were obtained from each histological preparation. Using the software HistMorph v.2.2, Image Tool v.2.00, the following was performed on micro photos: assessment of inflammatory response, assessment of cellular

*Address for Correspondence: Dr. George Sulamanidze, Head of Scientific Department, V. Orbeliani street 20/4, 0105 Tbilisi, Georgia, Tel: +99532 2920371/Ext 521; E-Mail: aptos@aptos.ru

Received: June 7th, 2019; Date Accepted: June 20th, 2019; Date Published: June 21st, 2019.

composition, assessment of collagen and elastin fibers, and determination of percentage ration of collagen types. With the help of software package Statistica v.7, basic statistical calculations were performed.

Results of studies

Control group

Macroscopy: On each dates of conclusion, an inflammatory process on macroscopic level was not detected. Skin and subcutaneous fatty cellular tissue are not pathologically altered.

Microscopy: During a histological study of glass slides, stained with hematoxylin and eosin [Figure 1 & 2 (A, B)], in the control group on different dates of implantation, no pathological altering of cellular composition was detected.

During the study of histological glass slides, stained according to Weigert-Van Gieson method, the occurrence of elastin and collagen fibers was detected, as in the depth of derma, as well as in connective tissue interlayers of subcutaneous fatty cellular tissue [Table 1, Figure 1 & 2 (C, D)]. This samples were samples for comparison.

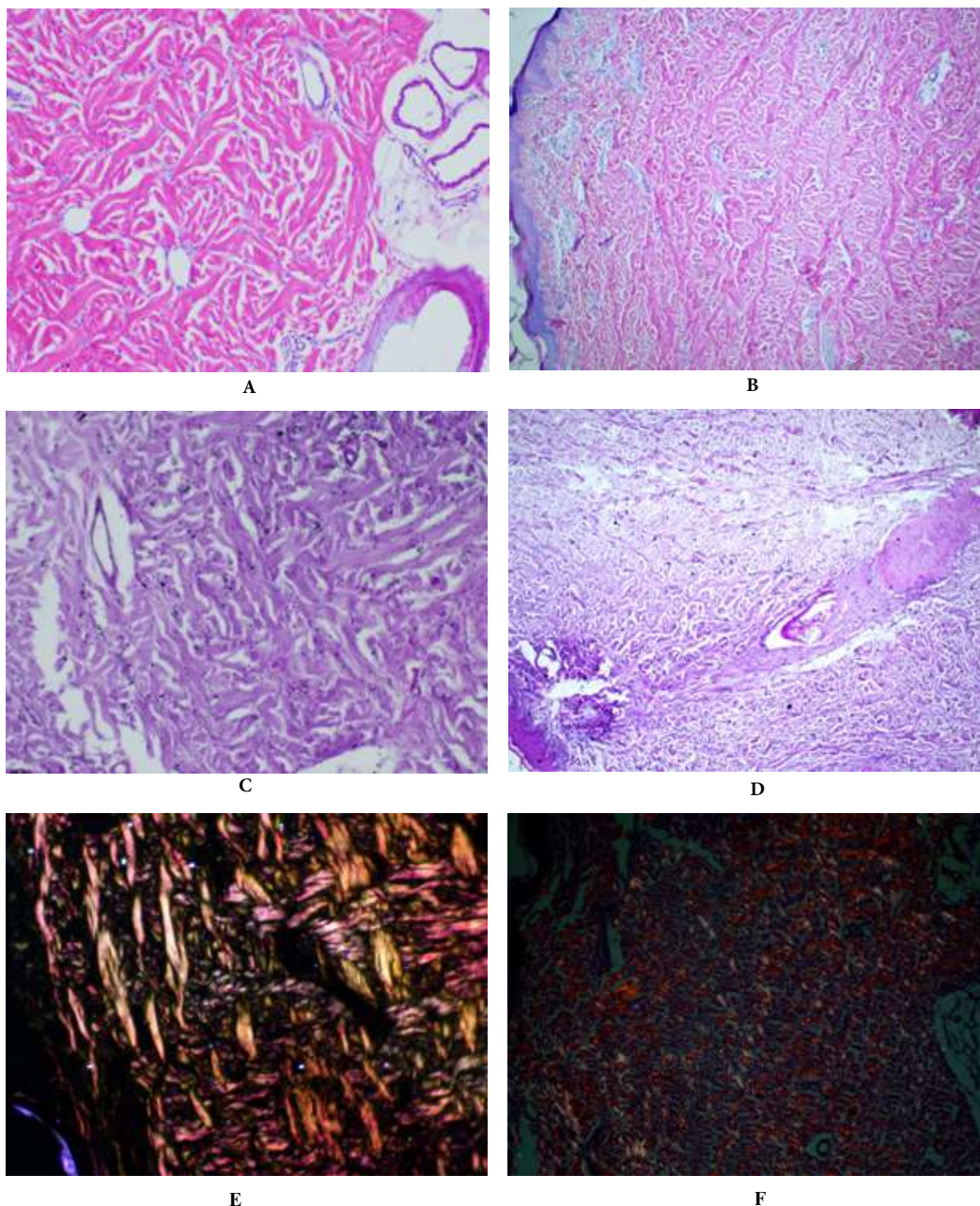


Figure 1: Control group, skin. A. Collagen fibers, 14 days, stained with hematoxylin and eosin, x200; B. Collagen fibers, 1 year, stained with hematoxylin and eosin, x100; C. Elastin fibers, 14 days, stained according to Weigert-Van Gieson method, x200; D. Elastin fibers, 1 year, stained according to Weigert-Van Gieson method, x100; E. 1. Collagen of III type, 2. Collagen of I type, 14 days, stain Sirius Red, x200; F. 1 year, stain Sirius Red, x100.

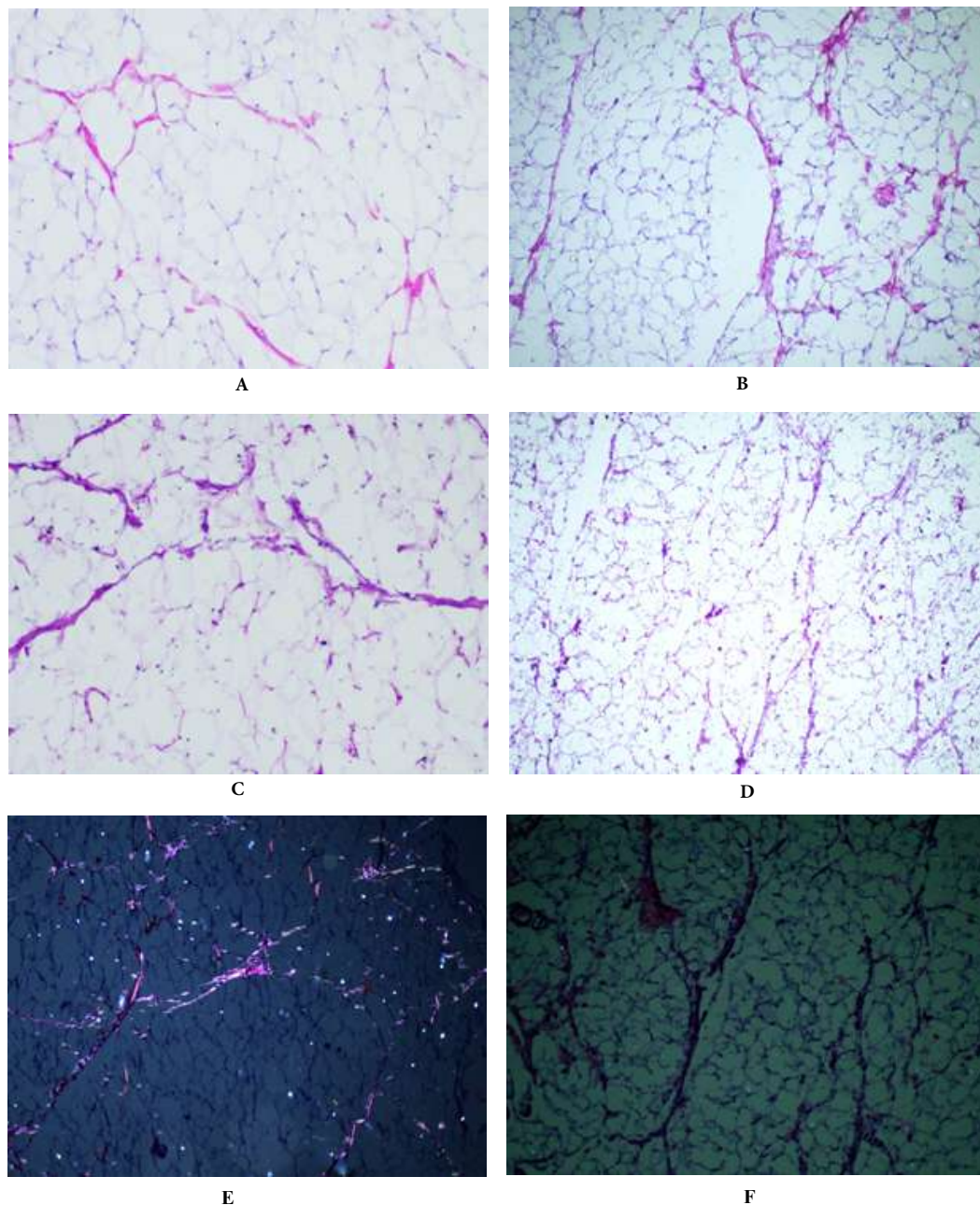


Figure 2: Control group, subcutaneous fatty cellular tissue (SFCT). A. Collagen fibers, 14 days, stained with hematoxylin and eosin, x200; B. Collagen fibers, 1 year, stained with hematoxylin and eosin, x100; C. Elastin fibers, 14 days, stained according to Weigert-Van Gieson method, x200; D. Elastin fibers, 1 year, stained according to Weigert-Van Gieson method, x100; E. 1. Collagen of III type, 2. Collagen of I type, 14 days, stain Sirius Red, x100; F. 1 year, stain Sirius Red, x100.

During the study of histological glass slides, stained with Sirius Red, an initial percentage ration of collagen fibers of I and III types was determined [Figure 1 & 2 (E, F)]. During the study of histological glass slides in polarized light: collagen of I type is lighted up with red spectrum of light; collagen of III type is lighted up with green spectrum of light. We obtained the following results [Table 1, Figure 3].

Thus, a steadily manifested growth of I type collagen in skin is detected, and the most active growth is detected during the first month of the experiment. Collagen of III type also tended to the sharp growth

during the first month and reached maximal values at the end of 1 year of the experiment. In subcutaneous fatty cellular tissue, a percentage ration of I type collagen had lower values, but a dynamic was completely replicated. Collagen of III type had a sharp growth until 60 days, with following decrease at the end of first year of the experiment.

Total amount of elastin fibers in skin during the whole experiment had a weak tendency to growth. In subcutaneous fatty cellular tissue, the amount of elastin fibers was growing only until 60 days from

Table 1: Dynamic of percentage ration of collagens of I and III types in skin and SFCT

	14 days. (M±m)	30 days (M±m)	60 days (M±m)	90 days (M±m)	1 year (M±m)
Skin Collagen I type	23.09±4.36	30.40±5.57	30.60±4.60	29.63±6.62	31.42±6.61
Skin Collagen III type	14.79±3.44	18.37±1.10	19.91±2.29	20.73±1.05	21.54±2.20
Skin Elastin fibers	1.35±0.30	1.74±0.17	1.79±0.15	1.80±0.17	1.81±0.17
SFCT Collagen I type	2.24±0.26	2.08±0.49	2.19±0.31	3.52±0.52	3.35±0.30
SFCT Collagen III type	9.27±4.66	18.3±2.18	18.49±0.51	7.41±1.17	6.78±0.94
SFCT Elastin fibers	0.23±0.10	0.31±0.10	0.29±0.05	0.25±0.04	0.22±0.04

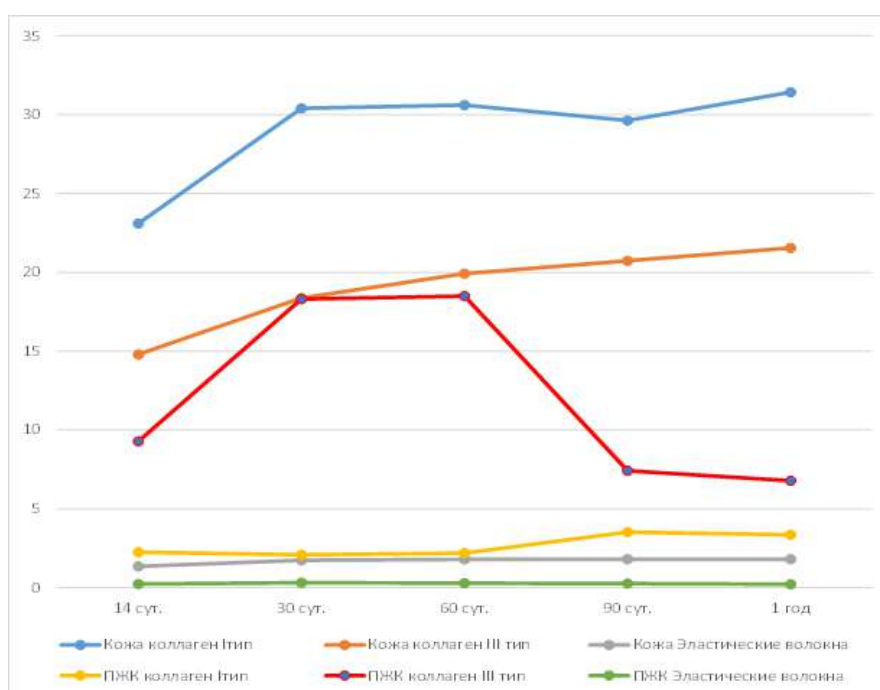


Figure 3: Dynamic of percentage ratio of collagen of I and III types in skin and subcutaneous fatty cellular tissue. [Skin Collagen of I type Skin Collagen of III type Skin Elastic fibers SFCT Collagen of I type SFCT Collagen of III type SFCT Elastic fibers]

the start of the experiment, with following decrease at the end of first year. This fact is explained by the growth of adipocytes, which make a main area of subcutaneous fatty cellular tissue.

PLA

Macroscopy

On all dates of conclusion, an inflammatory process on macroscopic level was not detected. Threads are not visualized under skin. Skin and subcutaneous fatty cellular tissue are not pathologically altered.

Microscopy

During a histological study of glass slides, stained with hematoxylin and eosin, no pathological altering of cellular composition in skin

was detected [Figure. 4 & 5 (A, B)]. Starting from 60 days, structural changes was occurring in skin, in the form of structuration of collagen fibers; they were becoming more manifested, intertwined with each other in mutually perpendicular directions.

Implanted thread, already on the 14th day, was surrounded by the interlayer of connective tissue (81.79 μm). At 30th day, the thickness of capsule reached maximal values (120.50 μm) with following decrease of thickness at 60th day to 53.39 μm . At 90th day the thickness reached 54.16 μm , at the end of first year this value was in average 49.52 μm . The increase of capsule's thickness at 30th day can be explained by active processes of formation of own connective tissue and response on foreign body, high number of fibroblasts and fibrocytes. Decrease of thickness at 60th day is explained by maturation of connective tissue, its structuration and decrease of

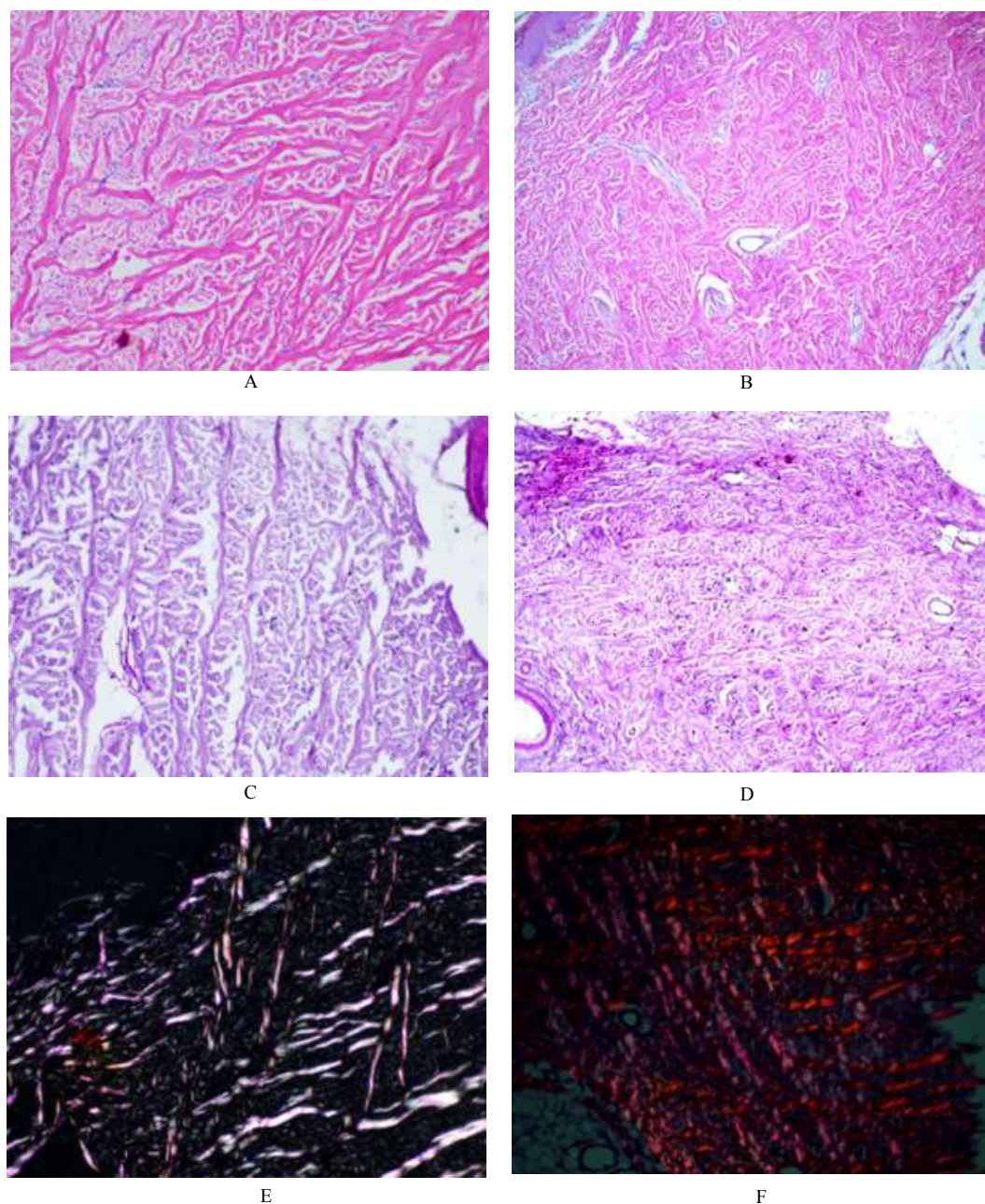


Figure 4: PLA, skin. A. Collagen fibers,14 days, stained with hematoxylin and eosin, x200; B. Collagen fibers,1 year, stained with hematoxylin and eosin, x100; C. Elastin fibers,14 days, stained according to Weigert-Van Gieson method, x200; D. Elastin fibers, 1 year, stained according to Weigert-Van Gieson method, x100; E. 1. Collagen of III type, 2. Collagen of I type, 14 days, stain Sirius Red, x200; F. 1 year, stain Sirius Red, x100.

number of fibroblasts. Starting from 30th day, in addition to structural changes, an increase of lymphohistiocytic infiltration was detected, which probably is the evidence of negative impact-mechanical pressure of implant on adjacent tissues.

The study of histological glass slides, stained according to Weigert-Van Gieson method, the occurrence of elastin fibers was detected, as in the depth of derma, as well as in connective tissue interlayers of subcutaneous fatty cellular tissue, but in low percentage ratio [Table 2] [Figure 4, & 5 (C, D)]. Study of elastin fibers in skin

brought to light a statistically reliable ($p<0.05$) increase of their amount from 14th day to 30th day, with following decrease at the end of first year of the experiment. In subcutaneous fatty cellular tissue, an area of elastin fibers was growing until 60th day, with the following decrease.

Study of collagen types showed [Figure. 4 & 5 (E, F)], that in skin from 14th day to 30th day, a decrease of collagen of I and III types occurs, with a following, statistically reliable ($p<0.05$) growth at the end of first year. In subcutaneous fatty cellular tissue a sharp, statisti-

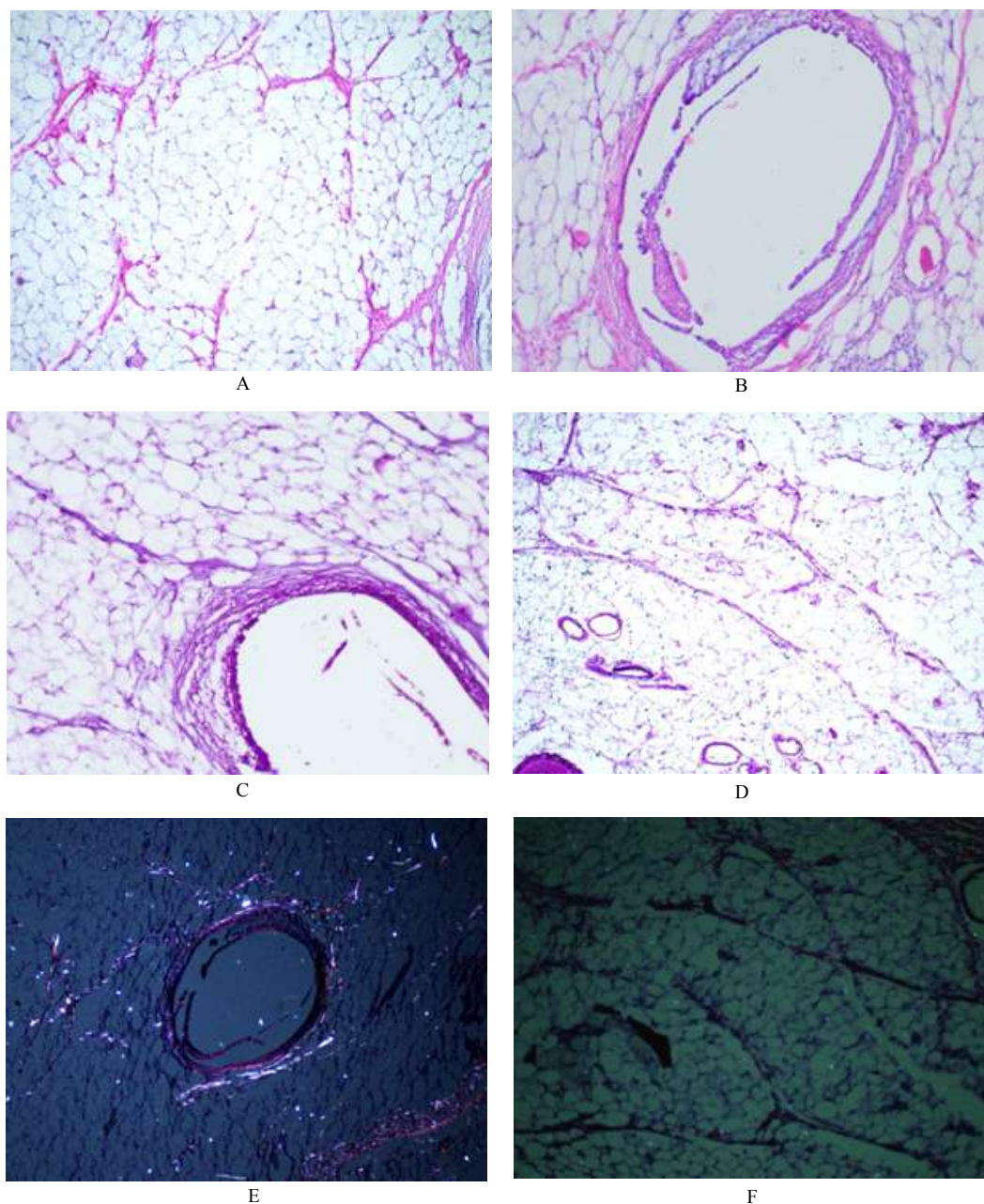


Figure 5: PLA, SFCT. A. Connective tissue capsule around the thread, 14 days, stained with hematoxylin and eosin, x200; B. Connective tissue capsule around the thread, 1 year, stained with hematoxylin and eosin, x100; C. Connective tissue capsule around the thread, 14 days, stained according to Weigert-Van Gieson method, x200; D. 1 year, stained according to Weigert-Van Gieson method, x100; E. Connective tissue capsule around the thread, 14 days, stain Sirius Red, x100; F. Connective tissue capsule around the thread, 1 year, окраска stain Red, x100.

cally reliable ($p < 0.05$) growth of III type collagen occurs until 60th day, with a following decrease at 365th day [Figure. 6]. Collagen of I type, in statistically reliable manner ($p < 0.05$), was growing until 90th day, and after this was slightly decreasing at the end of first year. Dynamic of III type collagen in skin proves a positive impact of implant, because exactly this type of collagen improves elastic characteristics of skin. Changes in subcutaneous fatty cellular tissue are probably associated with leucocyte response on a foreign body.

Thus, comparing the control group and PLA, the conclusion can be drawn on more positive impact of PLA sample on skin. Number of

elastic fibers, in skin as well as in subcutaneous fatty cellular tissue grows steadily but not sharply, until 3rd month. After this, the number of elastic fibers was approximately the same with a slight tendency to decrease. However, some negative processes are detected in subcutaneous fatty cellular tissue, in the form of lymphohistiocytic infiltration as response on a foreign body. PLA material has an impact on a higher formation of collagen of all types and formation of elastic fibers at all stages of the experiment, which improved elastic characteristics of skin, characteristic for “juvenile” skin and subcutaneous fatty cellular tissue.

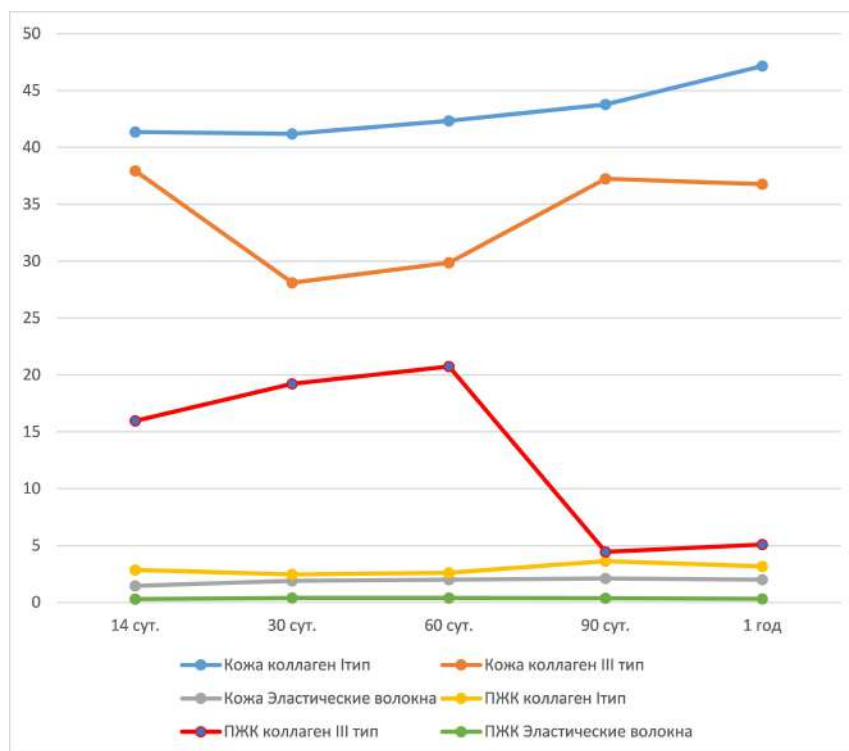


Figure 6: Dynamic of percentage ration of collagen of I and III types in skin and SFCT.

[Skin Collagen of I type Skin Collagen of III type
Skin Elastic fibers SFCT Collagen of I type
SFCT Collagen of III type SFCT Elastic fibers]

Table 2: Dynamic of percentage ration of collagen of I and III types in skin and SFCT.

	14 days (M±m)	30 days (M±m)	60 days (M±m)	90 days (M±m)	1 year (M±m)
Skin Collagen I type	41.37±7.91	41.20±9.01	42.35±5.16	43.79±1.23	47.17±5.11
Skin Collagen III type	37.94±4.43	28.10±6.52	29.87±1.19	37.25±1.45	36.77±0.85
Skin Elastic fibers	1.46±0.18	1.91±0.13	2.01±0.05	2.12±0.10	2.01±0.07
SFCT Collagen I type	2.86±0.46	2.46±0.48	2.62±0.29	3.64±0.24	3.18±0.23
SFCT Collagen III type	15.96±5.67	19.22±3.80	20.75±2.36	4.45±1.06	5.10±1.05
SFCT Elastic fibers	0.29±0.06	0.40±0.06	0.41±0.02	0.38±0.04	0.32±0.07

PLAHA 1%

Macroscopy

On all dates of an inflammatory process on macroscopic level was not detected. Threads are not visualized under skin. Skin and subcutaneous fatty cellular tissue are not pathologically altered.

Microscopy

During a histological study of glass slides, stained with hematoxylin and eosin, no pathological altering of cellular composition in skin was detected [Figure 7 & 8 (A, B)]. Starting from 60 days, structural changes was occurring in skin, in the form of structuration of collagen fibers; they were becoming more manifested, intertwined with each other in mutually perpendicular directions.

Implanted thread, already on the 14th day, was surrounded by the interlayer of connective tissue (91.31 μm). At 30th day, the thickness

of capsule reached maximal values (89.00 μm) with following decrease of thickness at 60th day to 94.82 μm . At 90th day the thickness reached 86.07 μm , at the end of first year this value was in average 70.57 μm . The dynamic of thickness of connective tissue capsule had a wavy form, with a tendency to decrease. This dynamic is typical for a normal course of encapsulation of material, without inflammation and collagenosis.

During the study of histological glass slides, stained according to Weigert-Van Gieson method, the occurrence of elastin fibers was detected, as in the depth of derma, as well as in connective tissue C, D)].

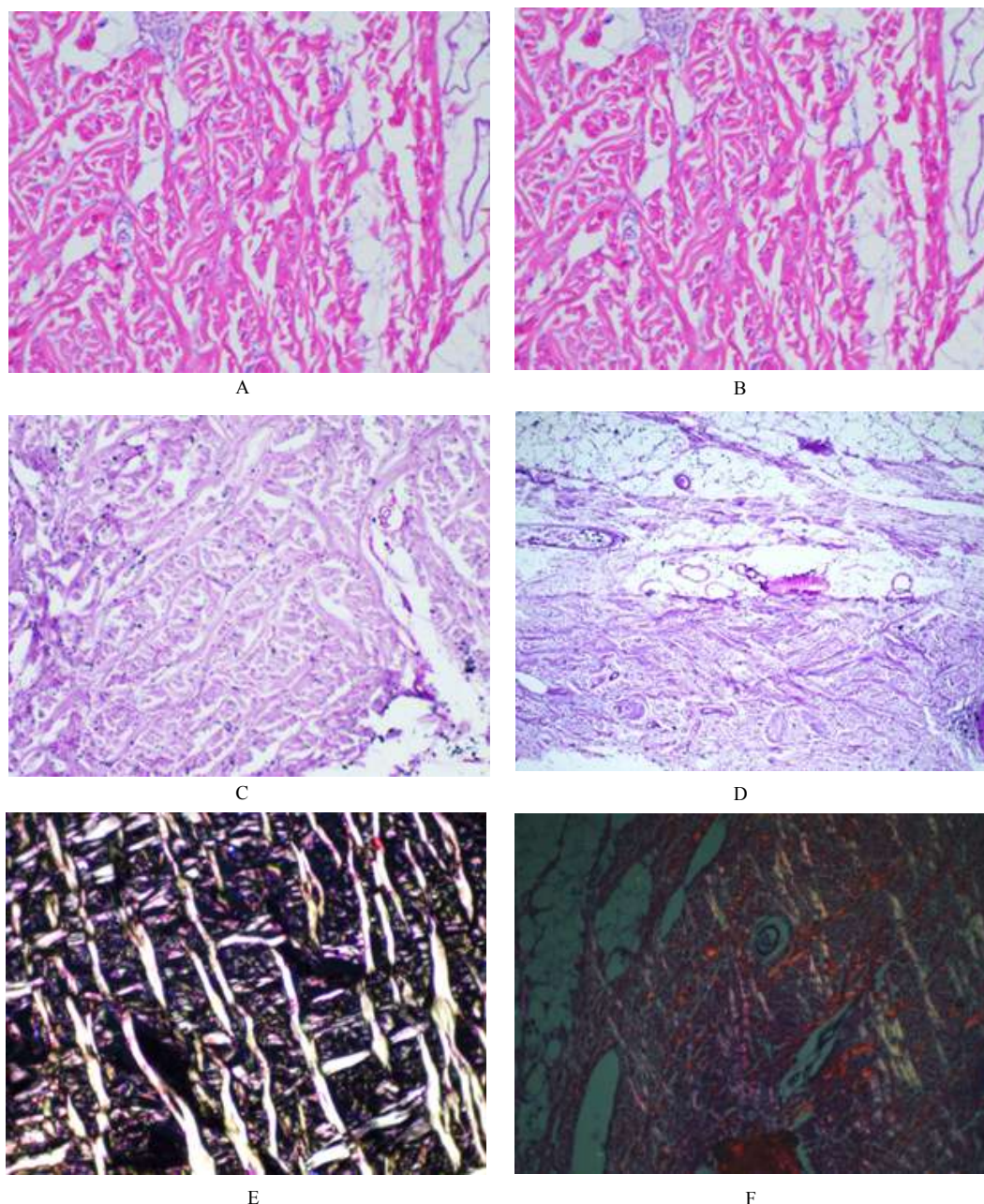


Figure 7: PLA HA 1%, skin. A. Collagen fibers, 14 days, stained with hematoxylin and eosin, x200; B. Collagen fibers, 1 year, stained with hematoxylin and eosin, x100; C. Elastin fibers, 14 days, stained according to Weigert-Van Gieson method, x200; D. Elastin fibers, 1 year, stained according to Weigert-Van Gieson method, x100; E. 1. Collagen of III type, 2. Collagen of I type, 14 days, stain Sirius Red, x200; F. 1 year, stain Sirius Red, x100.

After 14th day from the start of the experiment, the number of elastic fibers, at first in subcutaneous fatty cellular tissue and then in skin started to grow. After 30th day, the rate of formation of elastic fibers somehow decreased, but remained on quite high level. Maximal number of elastic fibers was reached at the end of 1 year.

Study of collagen types showed [Figure 8 & 9 (E, F)], that in skin from 14th day to 30th day, a smooth growth of collagen of I type occurs, with a following, decrease at the end of first year [Figure 9]. The amount of collagen of I type was maximal on 14th day, with following decrease at the end of year of the experiment. In subcutaneous fatty cellular tissue III type collagen was growing until 90th day,

with a following decrease at 36th day [Figure 6]. Collagen of I type has a wavy dynamic with peaks of growth at 14th day, 60th day and at the end of year. This implant did not cause a response on a foreign body. At 90th day a biodegradation and biointegration was detected.

When comparing the control group and PLA HA 1% material, the conclusion can be drawn on more positive impact of the latter on skin and subcutaneous fatty cellular tissue. PLA HA 1% material to a greater extent stimulated a formation of elastic fibers, especially intensively: in subcutaneous fatty cellular tissue during the first two months; in skin starting from the half of first month to three months. Despite the fact that after three months the dynamic of formation of

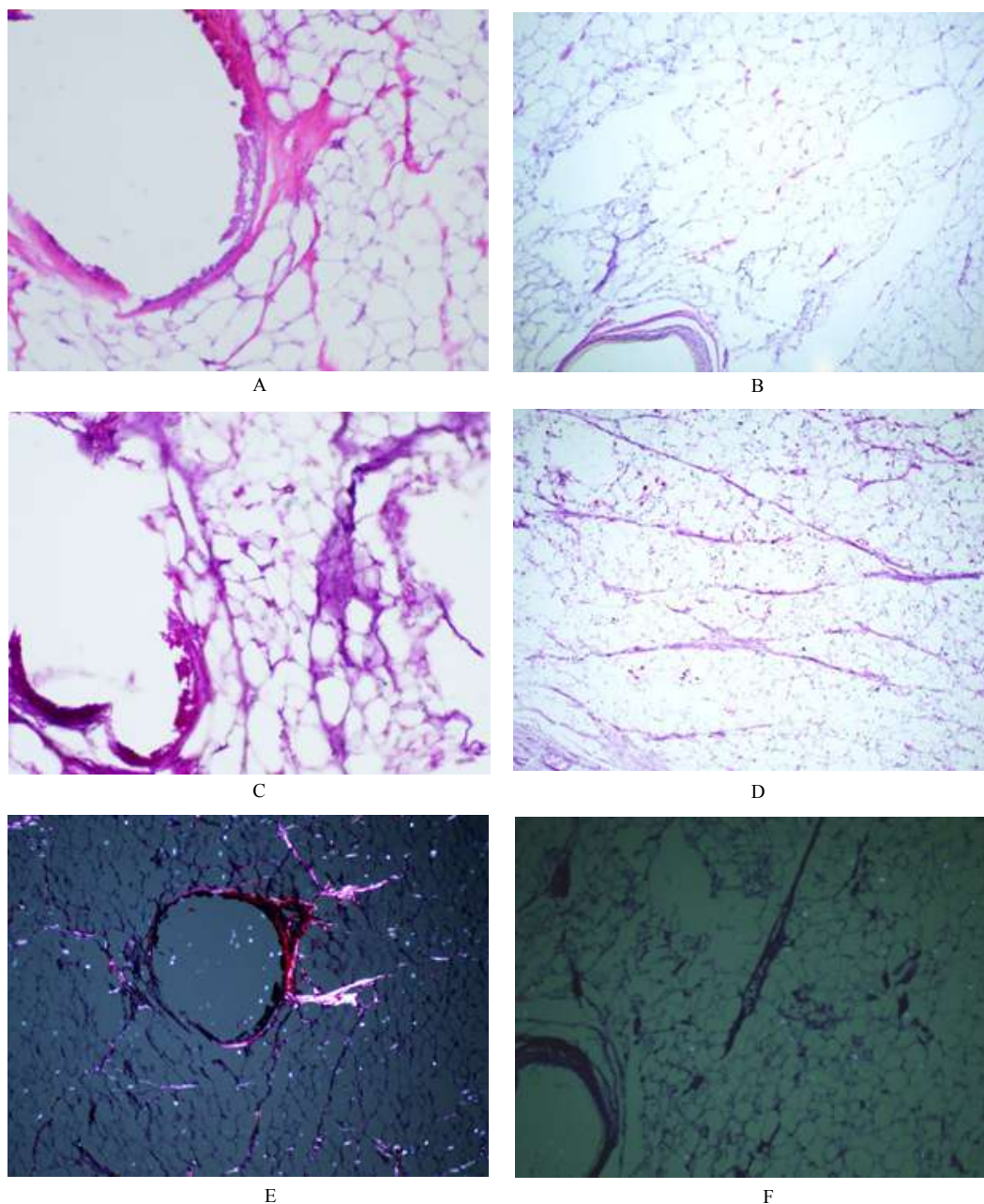


Figure 8: PLA HA 1%, SFCT. A. Connective tissue capsule around the thread, 14 days, stained with hematoxylin and eosin, x200; B. Connective tissue capsule around the thread, 1 year, stained with hematoxylin and eosin, x100; C. Connective tissue capsule around the thread, 14 days, stained according to Weigert-Van Gieson method, x200; D. 1 year, stained according to Weigert-Van Gieson method, x100; E. Connective tissue capsule around the thread, 14 days, stain Sirius Red, x100; F. Connective tissue capsule around the thread, 1 year, okpacka stain Red, x100.

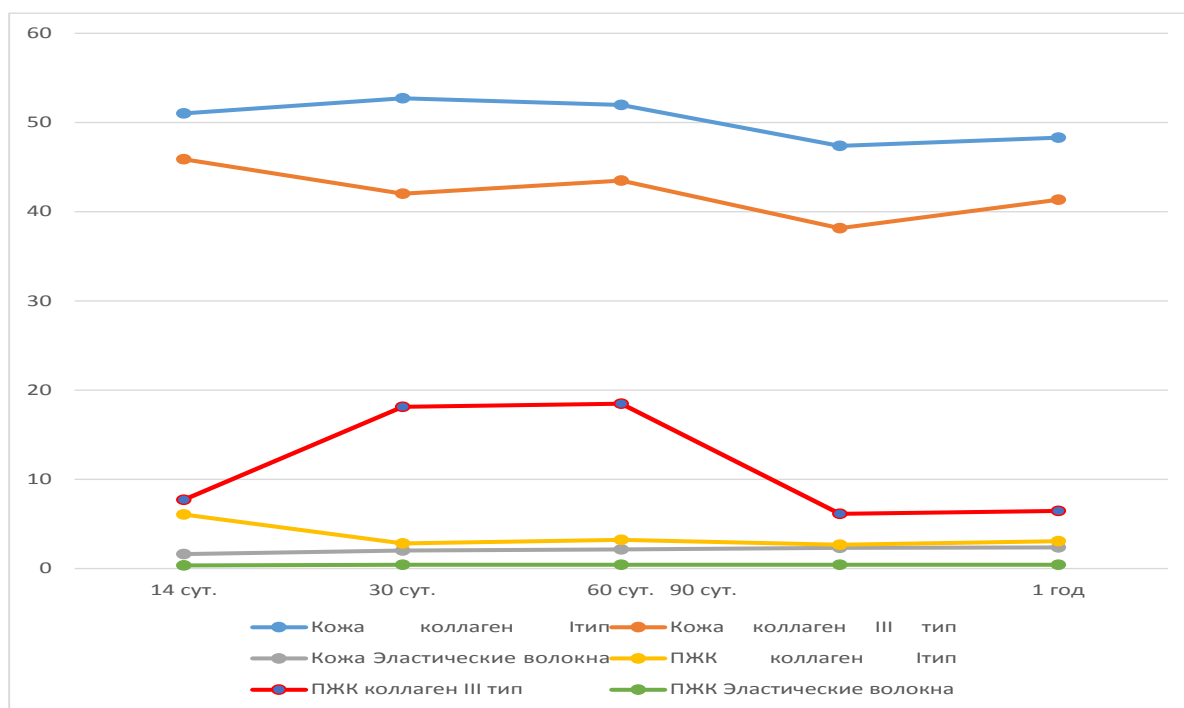


Figure 9: Dynamic of percentage ratio of collagen of I and III types in skin and SFCT. [Skin Collagen of I type Skin Collagen of III type. Skin Elastic fibers SFCT Collagen of I type SFCT Collagen of III type SFCT Elastic fibers]

Table 3: Dynamic of percentage ratio of collagen of I and III types in skin and SFCT

	14 days (M±m)	30 days (M±m)	60 days (M±m)	90 days (M±m)	1 year (M±m)
Skin Collagen I type	41.37±7.91	41.20±9.01	42.35±5.16	43.79±1.23	47.17±5.11
Skin Collagen III type	37.94±4.43	28.10±6.52	29.87±1.19	37.25±1.45	36.77±0.85
Skin Elastic fibers	1.46±0.18	1.91±0.13	2.01±0.05	2.12±0.10	2.01±0.07
SFCT Collagen I type	2.86±0.46	2.46±0.48	2.62±0.29	3.64±0.24	3.18±0.23
SFCT Collagen III type	15.96±5.67	19.22±3.80	20.75±2.36	4.45±1.06	5.10±1.05
SFCT Elastic fibers	0.29±0.06	0.40±0.06	0.41±0.02	0.38±0.04	0.32±0.07

elastic fibers slowed, it remained steadily positive. It is one of criteria of a superiority of PLA HA 1% material over PLA material. In addition to this, PLA HA 1% material had higher percentage ratio between collagen of I and III types at each dates of conclusion, therefore, this material improves elastic characteristics of skin, typical for “juvenile” skin and SFCT. During the use of this material, collagen fibers were generated in earlier periods of time and in higher amount.

Conclusion

Thus, the results of histological studies showed an effectiveness of use of PLA and PLA HA 1% materials, unlike of control group. However, unlike PLA material, PLA HA 1% material had advantages. First, it has better bioinert characteristics, which was manifested in the absence of local reaction on implant. This feature results in shorter rehabilitation period after a procedure.

Quantitative analysis showed more intense neocollagenesis at early stages after the implantation of thread. During the use of PLA HA 1% material, statistically reliable ($p < 0.05$), higher amount of collagen of both types is generated. Having a wavy dynamic, this material supports longer period of high content of collagen.

Generation of collagen was stimulated in greater amount as a response on PLA HA 1%. Formation of elastic fibers was detected in especially intense way during the first three months, in skin and in subcutaneous fatty cellular tissue. Despite the fact that after some time the dynamic of formation of elastic fibers slowed, it remained steadily positive.

Proceeding from the above-mentioned, we can conclude with certainty, that PLA HA 1% material had an advantage of PLA material, helping to collagen and elastin formation, which results in an occurrence of more manifested "rejuvenating" effect at early stages of thread implantation.

References

1. Sulamanidze M, Sulamanidze G. Lifting soft tissues: old philosophy, new approach—a method of internal stitching (Aptos needle). *J Jap Soc Aesth Surg*. 2005; 42: 182. [\[Crossref\]](#)
2. Sulamanidze M, Paikidze T, Sulamanidze G. et al. Utilisation du fiAPTOS dans le lifting facial. *Rev Chir Esthet*. 2001; 103: 17-22. [\[Crossref\]](#)
3. Luis Manuel Orozco-Castellanos, Angel Marcos-Fernández, Antonio Martínez-Richa. Hydrolytic degradation of poly (ϵ -caprolactone) with different end groups and poly(ϵ -caprolactone-co- γ -butyrolactone). Characterization and kinetics of hydrocortisone delivery. *Poly Adv Technol*. 2011; 22: 430-436. [\[Crossref\]](#)
4. Sulamanidze MA, Fournier PF, Paikidze TG, Sulamanidze GM. Removal of facial soft tissue ptosis with special threads. *Dermatol Surg*. 2002; 28:367-371. [\[Crossref\]](#)
5. Морфологическое обоснование подтяжки кожи лица спомощью нитей Aptos. Адамян А., Скуба Н., Суламанидзе М. и др. *Анналы пластической, реконструктивной и эстетической хирургии* 2002; [\[Crossref\]](#)
6. Методы Aptos: этапы омоложения. Интернет-ресурс: Суламанидзе М., Суламанидзе Г. Подтяжка мягких тканей лица с помощью нитей. *Инъекционные методы в косметологии* 2010, 2: 38-44. [\[Crossref\]](#)
7. Soft tissue compartments—face aging base; etiology of tissue ptosis and how to fight against it properly and this work is based on three-year anatomical research. Sulamanidze GM, Kajaia AA, *J Aesthet Reconstr Surg*. 2017; 3:2. [\[Crossref\]](#)
8. Sulamanidze M, Sulamanidze G. Facial lifting with Aptos Methods. *J Cutan Aesthet Surg*. 2008; 1: 7-11. [\[Crossref\]](#)
9. Sulamanidze M, Sulamanidze G. APTOS suture lifting methods: 10 years of experience. *Clin Plast Surg*. 2009; 36: 281-306. [\[Crossref\]](#)
10. Современный подход к моделированию лица: нити Aptos Excellence Visage в руках дерматокосметолога. Каджая А. Суламанидзе Г. Паикидзе Т. Суламанидзе М. Издание: Эстетическая медицина, 2012.-N 4.-С.505-512. Библ. 11 назв. [\[Crossref\]](#)
11. Sulamanidze G M and Kajaia A A. Soft tissue compartments—face aging base; etiology of tissue ptosis and how to fight against it properly and this work is based on three-year anatomical research. *J Aesthet Reconstr Surg*. 2017. [\[Crossref\]](#)
12. M Turkevych A, Kadjaya A, Gold MH, Lotti T, Sulamanidze G. Pathomorphological criteria of use efficiency of resorbable and permanent implants in aesthetic medicine and cosmetic dermatology. 2018. 17; 731-735. [\[Crossref\]](#)
13. Sulamanidze GM, Sulamanidze MA, Sulamanidze KM, Kajaia AA, Giorgadze SG. The Subcutaneous Tissue Reaction on Poly (L-lactide-co-caprolactone) based Threads; *Int J Clin & Exper Dermatol*. 2018; 3: 1-9. [\[Crossref\]](#)
14. Sulamanidze M, Sulamanidze G, Sulamanidze C. Elimination of Aesthetic Deformations of the Midface Area Our Experience. *Aesthetic Plastic Surgery. Int J Clin Expl Dermatol*. 2018; 3: 8-9. [\[Crossref\]](#)
15. Cutright DE, Hunsuck EE. Tissue reaction to the biodegradable polylactic acid structure. *Oral Sur Oral Med Oral Pathol*. 1971; 3: 134-139. [\[Crossref\]](#)