



ELSEVIER



REVIEW

## Breast augmentation: Part II – adverse capsular contracture

M.G. Berry\*, V. Cucchiara, D.M. Davies

*Institute of Cosmetic and Reconstructive Surgery, 1 Parkside, London W6 0UU, UK*

Received 17 November 2009; accepted 11 April 2010

### KEYWORDS

Breast augmentation;  
Adverse capsular contracture;  
ACC;  
Mammary prosthesis

**Summary** Although adverse capsular contracture (ACC) following breast augmentation remains an enigmatic phenomenon, significant progress has been made in diminishing its occurrence during the previous surgical generation. Given the rising global frequency of breast augmentation, however, ACC is likely to be with us for the foreseeable future and an understanding of its nature, and particularly prevention, will continue to be of foremost importance as breast augmentation undergoes a paradigm shift from anti-contracture to aesthetic result as the key outcome measure. Whilst clinical research has hitherto been the mainstay of investigation, providing both understanding and practical guidance, further improvements may derive from new developments in the fields of immunology and molecular biology: convergence of these complementary avenues may eventually yield a non-surgical treatment for ACC. This review presents a summary of our extant knowledge, providing evidence where it exists and a consensus view where it does not. It aims at providing a sound comprehension of the underlying aetiopathology that has provoked the measures seen to date and guides selection of the appropriate therapeutic strategy, which will be expanded in a future review. © 2010 British Association of Plastic, Reconstructive and Aesthetic Surgeons. Published by Elsevier Ltd. All rights reserved.

The 1950s saw both the first report of potential clinical uses for silicone in Plastic Surgery<sup>1</sup> and direct experience of implanted 'pervious silicone' sponges in canine models.<sup>2</sup> In the latter, neither infection nor extrusion were observed, all implants retained their consistency and became encapsulated. This was the first observation of

encapsulation, a characteristic of silicone thought to distinguish it from other contemporaneous biomaterials. We now know that, despite being relatively inert, breast prostheses are no different from any foreign material implanted into the human body in their provocation of a protective immune reaction from the host. This 'foreign body response' (FBR) is universal and ideally removes, or failing that circumscribes, the 'irritant' material with fibrous tissue to prevent unwanted immune sequelae.<sup>3</sup> A capsule is therefore the 'necessary and universal

\* Corresponding author. Tel./fax: +44 208 735 6060/6061.  
E-mail address: [enquiries@aestheticus.co.uk](mailto:enquiries@aestheticus.co.uk) (M.G. Berry).

mechanism of body defence'.<sup>4</sup> Ordinarily beneficial, problems ensue when such capsules become pathologically active and undergo a 'constrictive fibrosis' that deforms their contents and impairs the aesthetic outcome (Figure 1).

Although the capsule was initially described as a bilayer, with an inner cellular layer adjacent to the implant and an outer collagenous layer,<sup>5</sup> a tri-laminar structure is now accepted with an intervening lamina comprising loose connective tissue and a rich cellular presence<sup>6</sup> (Figure 2). Despite detailed clarification of the cellular and molecular components of the capsule,<sup>7</sup> a clear correlation between either capsule thickness (Table 1)<sup>8–11</sup> or the presence and composition of an inflammatory infiltrate and degree of contracture<sup>4,11–13</sup> has not been universally demonstrated although there are numerous studies supporting this association. There are, however, histopathological differences between implant types that explain certain characteristics. In general, smooth implants have uniform capsules, thick collagen fibres and few cells whereas textured and polyurethane (PU)-coated implants show a more marked cellular component, often associated with giant cell granulomata.<sup>14</sup> Synovial-type metaplasia (STM) is seen predominantly with textured prostheses and this phenomenon may explain the increased mobility, and therefore reduced ACC in such devices.<sup>12,15,16</sup> The mechanism may be through proteoglycans, which have both been implicated in the genesis of STM and inhibit collagen lattice contraction.<sup>17</sup> The final common pathway through which the inflammatory response actually produces contracture centres on myofibroblasts.<sup>18</sup> These contractile cells are responsive to smooth muscle agonists (e.g., histamine) and antagonists (e.g., papaverine)<sup>19</sup> and possess a contractility that appears quantity-, time- and presence-related.<sup>20</sup> Collagen gel matrix wound contraction models have confirmed greater myofibroblast contraction in patients with severe hypertrophic scarring<sup>21</sup> indicating a patient-specific propensity for scar, and thus capsule, formation.

Silicone itself has been identified in three different forms in peri-prosthetic tissue:

- irregular, translucent, amorphous droplets
- intracellular droplets
- elastomeric fragments within giant cell granulomata

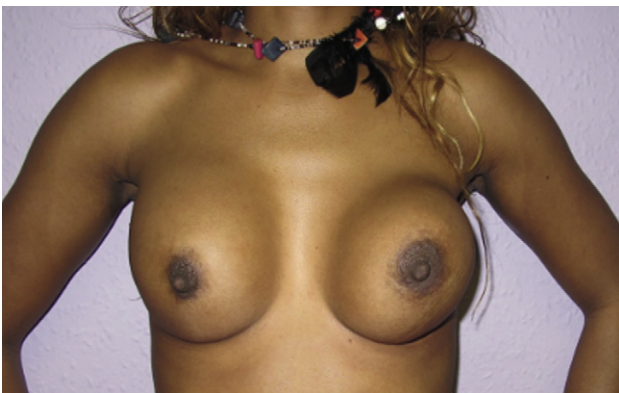

Figure 1 A typical example of Baker IV ACC.

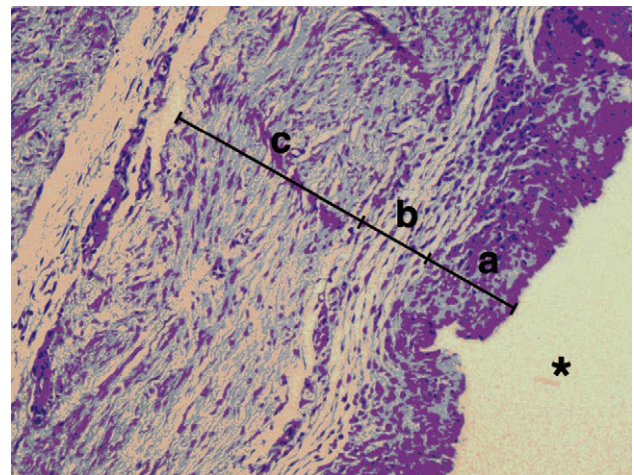


Figure 2 Capsular histopathology. (a) inner layer composed of fibrocytes and histiocytes forming an epithelial-like single layer, synovial-type metaplasia (STM). (b) intermediate layer of smaller fibrils in a vessel-rich network (i.e. loose connective tissue). (c) outer layer of densely packed collagen fibres lying parallel to the implant surface [taken from Minami E, Koh IHJ, Ferreira JCR et al. The composition and behaviour of capsules around smooth and textured breast implants in pigs. *Plast Reconstr Surg* 2006; 118: 874–84].

While the first two forms occur with all silicone gel filled implants, the third is relatively specific to textured surfaces, be they saline- or silicone-filled. It is assumed that granulomata result from attempted phagocytosis of particles shed from the elastomer and are extremely rare with smooth implants.<sup>15</sup> The impact of free silicone as a pathological entity is still debated, but there is little doubt that low-bleed gel implants have contributed to the decreased incidence of ACC. Giant cell granulomata appear as localised nodules, are more common with extra-capsular rupture and correlate with silicone leakage.<sup>11</sup>

## Aetiopathology

Upon implantation of any foreign material, opsonins immediately adsorb onto its surface allowing host immune cells to face a recognisable protein layer.<sup>3</sup> Even if too large for digestion some elements of the phagocytotic sequence do occur. Orchestrated by multiple immune cell-derived cytokines, the net result of fibroblast proliferation and collagen production is, as always, scar deposition and encapsulation. Should a state of chronic inflammation, perhaps through persistent inflammatory stimuli, motion or infection, supervene the fibrotic response becomes magnified. Additionally, inherent biomaterial properties, including geometry and surface chemistry, are capable of altering tissue response and healing reactions.<sup>3</sup> This facet has been successfully harnessed to combat ACC: physical modification and over-coating in the form of textured and PU-coated devices respectively. Pressure exerted on<sup>12</sup> and by an implant<sup>22</sup> also affects capsule formation, the latter principle being exploited by the latest generation, form-stable prostheses that provide resistance to the constrictive forces of an active capsule.<sup>23</sup>

**Table 1** Summary of documented capsule and clinical correlations

| Author               | Correlation ACC/thickness | Correlation ACC/inflammation | Correlation ACC/capsular silicone |
|----------------------|---------------------------|------------------------------|-----------------------------------|
| Wilflingseder (1974) | +                         | +                            | +                                 |
| Wagner (1977)        | N/A                       | +/-                          | N/A                               |
| Domanskis (1976)     | N/A                       | +                            | +                                 |
| Vistnes (1977)       | +                         | +/-                          | +                                 |
| Rudolph (1978)       | +/-                       | N/A                          | -                                 |
| Gayou (1979)         | -                         | -                            | +/-                               |
| Thomsen (1990)       | N/A                       | +                            | +                                 |
| Lossing (1993)       | +                         | +                            | N/A                               |
| Van Diest (1998)     | N/A                       | +                            | +                                 |
| Siggelkow (2003)     | +                         | +/-                          | -                                 |
| Prantl (2007)        | +                         | +                            | +                                 |

Historically, there have been two predominant, and somewhat artificially demarcated, investigative streams: the 'endogenous' and 'exogenous' hypotheses. Limitations of adopting one at the expense of the other have been cogently argued by Burkhardt, himself a declared proponent of the exogenous theory,<sup>24</sup> when he demonstrated the observed incidence of ACC to be less than expected with an intrinsic factor alone, but more than if an exogenous factor was solely responsible. ACC is, of course, multi-factorial, the two philosophies complimentary and an 'unified' hypothesis combining features of both logical.

### Endogenous hypothesis

Derangement of the normal healing reaction triggered by some unfavourable aspect of the host-implant interaction provides the basis for the endogenous hypothesis. Supporters believe this interface to be chiefly responsible for ACC based on the observation that it is not seen universally either between subjects or between individual breasts. As the majority never develop ACC, individual factors are clearly important if variable in their expression. Furthermore, were excessive contracture to be the result of prolonged or otherwise abnormal wound healing specific to a single individual, one would expect its occurrence bilaterally. No individual factor can explain the apparent randomness of the contracture, which is more commonly unilateral,<sup>24</sup> but seven elements, predominantly characteristics of the implant, have received attention:

- I. healing response modification
- II. elastomer composition
- III. implant content
- IV. elastomer surface
- V. polyurethane overcoating
- VI. anatomical plane of implantation
- VII. surgical technique

### Healing response modification

Early on little was known about any means of influencing the healing response in general, and ACC in particular, other than with corticosteroids. Peri-implant triamcinolone was first used in the 1970s,<sup>25</sup> however, adverse effects

including parenchymal thinning, implant extrusion and ptosis were alarmingly frequent.<sup>26</sup> Intra-implant methyl-prednisolone was substituted in order to obviate lower pocket pooling<sup>27</sup> and Ellenberg et al's reduction from 67.6 to 9.9%<sup>28</sup> prompted widespread use due to dismal ACC rates. Unfortunately, although the prevalence of ACC decreased, results were unpredictable and steroid-related complications sufficiently frequent to cause its abandonment.

### Elastomer composition

With ACC having long been associated with both vacuolar<sup>10</sup> and filler silicone,<sup>4</sup> and with silicone droplets being absent with saline-filled implants, the theory of silicone 'gel bleed' was born. In an elegantly simple experiment, intact implants placed on filter paper evidenced trans-elastomer silicone permeation.<sup>29</sup> Although silicone particles were later seen with saline-filled prostheses due to direct elastomer shedding,<sup>14</sup> gel bleed is held responsible for the particularly high ACC rates of first- and second-generation implants. The fluoro-silicone barriered, third-generation silicone and saline implants have certainly contributed to reductions in the incidence of ACC (Table 2). Recently introduced highly cohesive gels, have allowed further improvements, probably through a combination of further limiting trans-elastomer silicone permeation and a simple physical resistance to contraction.<sup>23,30</sup>

### Implant content

With the United States having banned silicone prostheses for augmentation in the 1990s, it has a wealth of experience with saline-filled devices and Rohrich's recent editorial was rather fulsome in its praise of them.<sup>31</sup> Although good evidence for a protective effect against ACC exists in both prospective<sup>32,33</sup> and retrospective, multicentre studies,<sup>34,35</sup> significant aesthetic downsides and high device failure rates have limited their acceptance elsewhere in the world. Interestingly, a swift rebuttal to the biased editorial swiftly followed<sup>36</sup> and with recent studies reporting that more women chose silicone-filled prostheses upon saline explantation<sup>37</sup> coupled with reports of elevated systemic side effects and a poorer overall function in reconstruction with saline,<sup>38</sup> the tide appears to be on the turn across the Atlantic.

**Table 2** Summary of ACC rates by implant generation according to elastomer surface and anatomical plane

| Author    | Year | Generation    | Number<br>p – patients<br>i – implants | FU (years) | ACC (%)  |        |              |             |                  | Re-operation<br>rate | Grade of<br>contracture |
|-----------|------|---------------|--|------------|----------|--------|--------------|-------------|------------------|----------------------|-------------------------|
|           |      |               |  |            | Textured | Smooth | Subglandular | Submuscular | Not<br>specified |                      |                         |
| Gylbert   | 1989 | 1st, 2nd, 3rd |  | 15–21      |          | +      | 79           | –           |                  |                      |                         |
| Vinnik    | 1976 | 2nd           | 289 p                                  | 1–3        |          | +      | 74           | –           |                  |                      | II, III, IV             |
| Hipps     | 1978 | 2nd           | 453 p                                  | >1         |          | +      | 32           | –           |                  |                      | II, III, IV             |
| Asplund   | 1984 | 3rd           | 65 p                                   | ½ – 2½     |          | +      | 55           | –           | 20               |                      | III, IV                 |
| McKinney  | 1983 | 2nd, 3rd      | 169 p                                  | 10         |          |        | 36           | –           | 24               |                      | III, IV                 |
| Gutowisky | 1997 | 3rd           | 504 p                                  | 6 (mean)   |          |        |              | –           | 20.4             |                      | III, IV                 |
| Scully    | 1981 | 2nd           |  |            |          | +      | 70           | 5           |                  |                      | III, IV                 |
| Puckett   | 1987 | 3rd           | 100 p                                  | <3         |          | +      | 48           | 14          |                  |                      | III, IV                 |
| Vazquez   | 1987 | 3rd           |  | 3          |          | +      | 58           | 9.4         |                  |                      | III, IV                 |
| Biggs     | 1990 | 2nd, 3rd      | 585 i                                  | 1          |          | +      | 11           | 3           |                  |                      | III, IV                 |
| Coleman   | 1991 | 3rd           | 53 p                                   | 1          | 8        | 58     | +            | +           |                  |                      | III, IV                 |
| Ersek     | 1991 | 2nd,3rd       | 228 p                                  | 2–12       | 5        | 45     | +            | +           |                  |                      | III, IV                 |
| Pollock   | 1993 | 3rd           | 197 p                                  | 3          | 4        | 21     | +            | –           |                  |                      | III, IV                 |
| Malata    | 1997 | 3rd           | 53 p                                   | 3          | 11       | 59     | +            | +           |                  |                      | III, IV                 |
| Hakelius  | 1997 | 3rd           | 25 p                                   | 1          | 0        | 44     | +            |             |                  |                      | BAC 3                   |
| Tarpila   | 1997 | 4th           | 21 p                                   | 1          | 29       | 38     | +            |             |                  |                      | III                     |
| Collis    | 2000 | 3rd           | 53 p                                   | 10         | 11       | 65     | +            | +           |                  |                      | III, IV                 |
| Fagrell   | 2001 | 4th           | 20 p                                   | 7.5        | 22       | 33     | +            |             |                  |                      | III, IV                 |
| Inamed-1  | 2007 | 5th           | 455                                    | 6          |          |        | 14.8         |             | 28               |                      | III, IV                 |
| Inamed-2  | 2007 | 5th           | 147                                    | 6          |          |        | 20.5         |             | 40.3             |                      | III, IV                 |
| Mentor-1  | 2007 | 5th           | 551                                    | 3          |          |        | 8.1          |             | 15.4             |                      | III, IV                 |
| Mentor-2  | 2007 | 5th           | 146                                    | 3          |          |        | 18.9         |             | 28               |                      | III, IV                 |
| Handel-1  | 2006 | 5th           | 825 p                                  | 10         |          |        | 1.99         |             | 15.5             |                      | III, IV                 |
| Handel-2  | 2006 | 5th           | 695 p                                  | 10         |          |        | 4.36         |             | 21.9             |                      | III, IV                 |
| Stevens   | 2008 | 5th           | 1012 i                                 | 13         | 2.6      |        | +(n = 30)    | ++          | 6.8              |                      | III, IV                 |
| Heden     | 2009 | 5th           | 163 p                                  | 11         | 5.3      |        | ++           | +           |                  |                      | III, IV                 |

### Elastomer surface

Texturisation of the silicone elastomer was prompted by the appreciably lower ACC rates seen with PU-coated implants<sup>39</sup> and early studies were strongly supportive.<sup>40–43</sup> Later studies provided a somewhat different view<sup>44,45</sup> and debate was for a time intense. Fortunately, some quality prospective studies are available to evidence the benefit of texturisation in the first year,<sup>41,46</sup> when the majority of contractures occur:<sup>47</sup> this benefit being maintained at 5<sup>47</sup> and 10 years.<sup>48</sup> Recently, a pair of meta-analyses calculated the overall benefit of textured implants to be an approximate five-fold reduction in ACC, maintained after three years<sup>49,50</sup> (Table 3).

As to the texturisation itself, it appears that some element is more important than the precise surface detail as long as pore size exceeds 300 µm.<sup>49</sup> From a clinical perspective, experience has shown a curious double-capsule effect with some textured implants, particularly McGhan: there is an apparent pseudo-encapsulation whereby the fibrous-coated implant appears to float within a second capsule, postulated to result from shearing forces separating a tightly adherent capsule.<sup>51</sup>

### Polyurethane overcoating

Polyurethane was originally applied as a coating for sponges found to be problematic in the 1950s. Initial reports were highly favourable (Table 4).<sup>52–55</sup> and the capsules appeared distinctly different from those surrounding silicone. The much reduced ACC was ascribed to a disruption in the normally parallel capsular collagen fibres, which inhibited circumferential contraction. There was also an increased cellular content and marked adhesion to the implant that resulted not from the textured surface per se, but particles of polyurethane that had become detached.<sup>56</sup>

As with textured silicone, long-term, homogenous data generated from PU-coated devices showed mixed results. Coney's single practice series showed ACC rates similar to silicone implants<sup>57</sup> whereas Handel's multi-surgeon study showed PU-coated implants to have very low rates, when compared with smooth or textured implants, but still rising to a level of 25% at 10 years.<sup>45</sup> The latter suggested PU-coated implants delayed rather than prevented the onset of ACC because of the gradual loss of the polyurethane overcoat. Again, as with silicone, PU-coated devices have themselves survived scaremongering with respect to the potential carcinogenic risk of the breakdown-product 2,4-toluenediamine (TDA), which was later shown not to be clinically significant.<sup>58,59</sup>

### Anatomical plane of implantation

The subglandular plane was the initial standard, not least for its 'anatomical' nature, however, implantation beneath pectoralis major, introduced to ameliorate extrusion and visibility following subcutaneous mastectomy,<sup>60</sup> was also found to greatly reduce the contracture rate.<sup>61</sup> With respect to ACC specifically, evidence exists for a significant reduction with the submuscular location independent of surface texture,<sup>48</sup> perhaps consequent upon the continuous massaging action of pectoralis major.<sup>61</sup> The musculofascial plane also affords protection, indirectly via reduced infection, from potentially pathogenic breast flora<sup>62</sup> and improves mammographic visualisation.<sup>63</sup> Although one might expect a greater effect from combining texturisation with submuscular placement, the sole study to evaluate this failed to reach statistical significance.<sup>42</sup>

### Surgical technique

Although clearly open to influence by personal technique there are some key elements whereby surgical decision-making may influence ACC. The first is the choice of incision and non-inframammary fold placement was associated with an almost 6-fold increase in the relative risk (RR) of ACC in one large prospective study.<sup>64</sup> Albeit retrospective, another study showed peri-areolar incisions to give a RR of 16, probably through violation of the mammary ductal system,<sup>65</sup> and patients in whom concurrent areolar reduction is deemed beneficial should be counselled accordingly.

Haematoma had fallen under suspicion previously<sup>66,67</sup> and Handel recently confirmed its correlation with ACC,<sup>45</sup> however, blunt dissection has, or should have, been entirely superseded by direct vision and meticulous haemostasis<sup>68</sup> to render this issue of lesser importance today, although a role for occult haematomata probably remains. Mirroring this, drains were found to be beneficial initially,<sup>67</sup> but the current low prevalence of ACC is associated with their avoidance.<sup>69–71</sup>

### Exogenous hypothesis

Proponents of the exogenous hypothesis cite infection as the leading cause for ACC<sup>72,73</sup> and although explaining asymmetric occurrence, the theory falls short of definitive causality. Overt infection is a rare event in BA, perhaps surprisingly so given the magnitude of the foreign body challenge, and much effort has been expended in studies

**Table 3** Meta-analysis of prospective studies comparing textured with smooth implants and the incidence of ACC (See Wong et al<sup>50</sup>)

|                  | Number (patients) | Follow up (%)           | Outcome         | Textured vs smooth ACC (%) |
|------------------|-------------------|-------------------------|-----------------|----------------------------|
| Hakelius (1992)  | 25                | 1 yr (100)              | Textured better | 0 vs. 40                   |
| Coleman (1991)   | 53                | 1 yr (94)               | Textured better | 8 vs. 58                   |
| Collis (2000)    | 33                | 3 yr (92)<br>10 yr (83) | Textured better | 11 vs. 59<br>11 vs. 65     |
| Tarpila (1997)   | 21                | 1 yr (90)               | No difference   | 29 vs. 38                  |
| Fagrell (2001)   | 18                | 7.5 yr (90)             | No difference   | 22 vs. 33                  |
| Burkhardt (1994) | 56                | 1 yr (87)               | Textured better | 2 vs. 40                   |



**Table 4** Incidence of ACC with PU-coated implants

|                             | Baker III-IV<br>ACC (%) | Number     | Follow up<br>(years) |
|-----------------------------|-------------------------|------------|----------------------|
| Capozzi (1991)              | 1.8                     | 54         | 6                    |
| Pennisi (1990) <sup>a</sup> | 2 vs. 22                | 85 vs. 115 | 11                   |
| Melmed (1988)               | 0.9                     | 320        | 6                    |
| Hester (1988)               | 0.2                     | 690        | 5                    |
| Gasperoni (1992)            | 3.3                     | 210        | 12                   |
| Vazquez (2007)              | 0.5                     | 404        | 10                   |
| Cohney (1991)               | 28                      | 173        | 5                    |
|                             | 58                      |            | 6–10                 |
|                             | 19                      |            | 18                   |
| Handel (2006)               | 25                      | 305        | 10                   |

<sup>a</sup> The two values refer to delayed and immediate reconstruction after subcutaneous mastectomy.

involving bacteriostatic and bacteriocidal agents. The former, in the shape of povidone-iodine, has been clearly shown to reduce ACC: Burkhardt's landmark trial, addressing two of Koch's postulates, showed that ACC was both caused by infection and could be inhibited by local povidone-iodine.<sup>73</sup> It also appears to possess a synergistic benefit when combined with antibiotics as a pocket irrigant,<sup>74</sup> but has been banned by the FDA due to concerns with elevated device rupture following intra-luminal administration. This prompted the combination of multiple antibiotics, which have produced even lower ACC rates.<sup>70</sup>

Beyond 'infection', in a non-specific sense, evidence has accumulated for the role of biofilms in mediating ACC.<sup>62,75</sup> Surface bacteria secrete a hydrated polymeric matrix in which they aggregate as sessile communities – the 'bio-film'<sup>76</sup> – which are much less conspicuous to the host immune system and provide an explanation for antibiotic-resistant and culture negative inflammation.<sup>75</sup> Positive culture rates in severely contracted capsules have been quoted as high as 89.5% compared to 10.5% in grade I/II contracture.<sup>62</sup>

### A unified view of ACC and potential non-surgical treatment modalities

If encapsulation is the normal end-point, then ACC is an aberrant healing response comprising a more active role for the immune system.<sup>7</sup> Fibroblasts and macrophages are the predominant capsular cell types in the inner layer, beneath which lie activated CD4+ and numerous antigen presenting cells. Overall, an important T-mediated immune response is postulated as the basis for encapsulation as serum samples from ACC patients have increased levels of cytotoxic activity,<sup>77</sup> but a clear and precise causal relationship has yet to be established.

The cytokine TGF- $\beta$  is topical and appears to play a fundamental role in numerous conditions characterised by excessive fibrosis, including keloid.<sup>78</sup> Both myofibroblasts and macrophages from ACC patients express  $\beta$ 1 and  $\beta$ 2 isoforms, indicating that the local capsular cytokine environment may be the long-sought missing trigger for abnormal inflammatory responses. TGF- $\beta$ 1 and  $\beta$ 2 levels,

and their downstream mediator, connective tissue growth factor, are higher in periprosthetic capsules.<sup>79</sup> TGF- $\beta$  inhibition, both with antibody-receptor<sup>80</sup> and antisense-mRNA blockade,<sup>81</sup> reduces skin scarring and ACC in animal models<sup>82</sup> and has been found to decrease capsule thickness.<sup>83</sup>

There are other unexpected avenues for potential research, for example angiotensin II, which has a range of effects beyond that of haemodynamic regulation. It protects against renal fibrosis<sup>84</sup> and ACE-inhibitors diminished inflammatory cell infiltrate, collagen III content, vessel density, TGF- $\beta$  immunostaining and capsule thickness in a recent rat study where, interestingly, textured performed uniformly better than smooth surfaced implants.<sup>85</sup> Leukotrienes are potent inflammatory mediators and their antagonists, including Zafirlukast, have been trialled with some success in early<sup>86</sup> and established ACC,<sup>87</sup> however, these agents are presently 'off label' for ACC and, in their usual guise of asthma prophylactics, have been somewhat alarmingly linked with reports of hepatic failure and death.<sup>88</sup> Finally, tissue remodelling matrix metalloproteinases (MMP) and their inhibitors (tissue inhibitor of metalloproteinase, TIMP), are altered in conditions associated with unbalanced ECM degradation. Concentrations of certain TIMPs was found to be elevated and the MMP:TIMP ratio reduced in ACC.<sup>89</sup> Intriguingly, hyaluronan levels correlate with Baker grade so may offer the possibility of a serum marker for ACC.<sup>89</sup>

### Classification

Several methods have been proposed for the assessment and quantification of ACC (Table 5). Baker's original clinical classification<sup>90</sup> underwent subtle modification to accommodate breast reconstruction and patient symptoms<sup>91</sup> and, despite the lack of critical validation, remains widely accepted. The present 'British standard' has been presented by Stone.<sup>92</sup> The Swedes favour the Breast Augmentation Classification (BAC), based on Baker's, but excluding the opinion of the patient.<sup>93</sup> Although subjective, grades I and II are considered acceptable and III and IV not, the latter two constituting adverse capsular contracture. Applanation tonometry is a more objective technique that measures breast displacement by a perspex disc of known weight<sup>94</sup> and has been shown to be more sensitive in detecting early contracture than the BAC,<sup>47</sup> but is not used routinely.

### The magnitude of the problem: prevalence of ACC

Breast implants have generated debate since their very introduction and, whilst the 1990's were devoted to safety concerns regarding autoimmune disease and cancer, the current focus has shifted to adverse local effects. While patient satisfaction with breast augmentation remains high,<sup>23,45</sup> the most frequent local complication is ACC, which, if not posing actual health risks, may be symptomatic, compromises the aesthetic outcome and frequently requires surgical intervention. Furthermore, patients with ACC are more likely to have it recur after revision, fuelling a vicious circle of poor outcomes.<sup>95</sup>

**Table 5** Comparison of subjective assessment methods of capsular contracture

| Baker              | Augmentation (1978)   | Spear                | Reconstruction (1995)   |
|--------------------|---|----------------------|---|
| Class I            | Absolutely natural; no one could tell breast augmented                              | Class IA<br>Class IB | Absolutely natural; cannot tell breast reconstructed<br>Soft, but implant detectable by palpation or inspection because of mastectomy |
| Class II           | Minimal contracture: I can tell surgery was performed, but patient has no complaint | Class II             | Mildly firm with an implant that may be visible or detectable by palpation  |
| Class III          | Moderate contracture; patient feels some firmness                                   | Class III            | Moderately firm with implant readily detectable, but result still acceptable  |
| Class IV           | Severe contracture; obvious from observation  | Class IV             | Severe contracture with unacceptable aesthetic outcome &/or significant symptoms necessitating surgical intervention                  |
| Gylbert<br>Grade I | Augmentation (1989)<br>Soft<br>No deformation                                       | Stone<br>Class I     | Augmentation (2001)<br>No contracture   |
| Grade II           | Slightly thickened consistency<br>None-to-slight deformation                        | Class II             | Palpable contracture  |
| Grade III          | Firm to hard<br>None-to-slight deformation  | Class III            | Visible contracture   |
| Grade IV           | Hard<br>Severe deformation  | Class IV             | Painful contracture   |

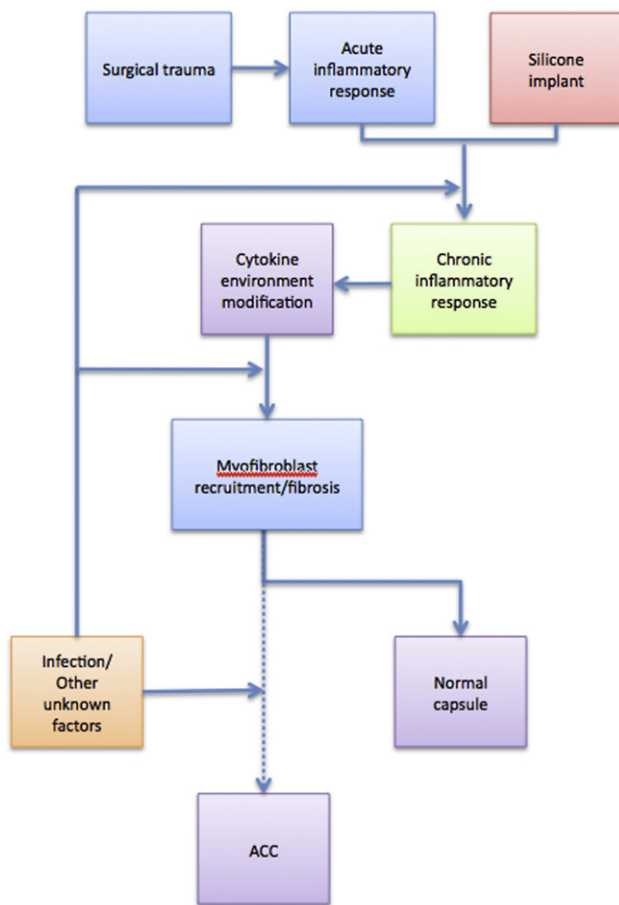
Fortunately, ACC rates have improved dramatically over the years (Table 2) even if the numerous generations, fillers and other variables make data extrapolation by necessity vague. Whilst thought to occur primarily in the first two years,<sup>16,47</sup> with some reporting a zero rate of delayed ACC,<sup>33</sup> extended surveillance shows that there is, in fact, a long-term, cumulative increase in ACC.<sup>45,47,48</sup> There are, however, recent studies that have addressed long-term follow up with homogeneous implants. Both Inamed ([www.allergan.com](http://www.allergan.com)) and Mentor ([www.mentorcorp.com](http://www.mentorcorp.com)) have released premarket, core study data.<sup>30,71</sup> Other single-institution or -surgeon, fourth-generation outcomes show encouraging results over 11<sup>23</sup> and 13 years respectively.<sup>96</sup> These results are summarised in Table 2 and, as is apparent, the prevalence of ACC remains not inconsequential indicating that a significant number of patients may well require revision surgery in the future.

## Discussion

As shown by the research currently available to us, ACC has a multifactorial and incompletely characterised aetiology. Surgical trauma initiates wound healing in the normal fashion, but this may be modified by inherent implant characteristics or the local milieu to produce an abnormal pathological outcome. In a fashion not dissimilar to oncogenesis, there may in some cases be a single initiator that is sufficiently potent to produce the effect alone, for example, frank infection. In others the initiator, perhaps

the biomaterial-host interface, may require potentiation by promoter(s), such as occult contamination or haematoma. Whatever the precise situation, such factors precipitate a chronic inflammatory reaction that stimulates a cascade resulting in propagation of the fibrogenic stimulus (Figure 3). In conclusion, a solid evidence base exists for avoiding direct contact between gel silicone and host tissues, by both the fluorinated and multilaminated elastomer and the high cohesivity of the gel itself. Texturisation or polyurethane coating are also proven reducers of ACC as is something antibacterial, previously povidone-iodine, today synergistic antibiotic combinations. The sub-muscular plane also appears clear-cut from an evidentiary view, but the additional depth and cover might simply mask ACC rather than reducing its prevalence per se. Surgeon-influenced aspects include operative precision, meticulous haemostasis and avoidance of haematoma with the need for drainage.

Whilst aetiologically not yet completely unravelled, the incidence of ACC has been brought to manageable levels and may soon become an endangered species helping to spare our patients further, and less predictable, surgical intervention some of the strategies of which will be explored in a future review. To borrow from Burkhardt ... 'hard breasts, soft data'<sup>97</sup> ... we can expect much softer breasts and are beginning to firm up on the aetiology of the sometimes capricious entity that is ACC. Paradoxically, as its occurrence diminishes fewer index cases to research may shift us further from the precise answer. In this respect, continued homogeneous, long-term studies yield



**Figure 3** A summary of the factors involved in the pathogenesis of ACC.

strong objective data on which to base discussion with the patient about possible outcomes of a procedure that remains one of the most satisfactory in cosmetic surgery.

## Conflict of interest

None.

## Funding

None.

## References

- Brown JB, Fryer MP, Randall P, et al. Silicones in plastic surgery. *Plast Reconstr Surg* 1953 Nov;12(5):374–6.
- Marzoni FA, Upchurch SE, Lambert CJ. *Plast Reconstr Surg* 1959;24:600–8.
- Biomaterials Science. An Introduction to Materials in Medicine*. 2nd ed. Elsevier Academic Press; 2004.
- Vistnes LM, Bentley JW, Fogarty DC. Experimental study of tissue response to ruptured gel-filled mammary prostheses. *Plast Reconstr Surg* 1977;59:31–4.
- Domanskis EJ, Owsley JQ. Histological investigation of the etiology of capsule contracture following augmentation mammoplasty. *Plast Reconstr Surg* 1976;58:689–93.
- Ginsbach G, Busch LC, Kuhnel W. The nature of collagenous capsules around breast implants. *Plast Reconstr Surg* 1979;64:456–64.
- Wolfram D, Rainer C, Niederegger H, et al. Cellular and molecular composition of fibrous capsules formed around silicone breast implants with special focus on local immune reactions. *J Autoimmun* 2004;23:81–91.
- Rudolph R, Abraham J, Vecchione T, et al. Myofibroblasts and free silicone around breast implants. *Plast Reconstr Surg* 1978;62:185–96.
- Gayou RM. A histological comparison of contracted and non-contracted capsules around silicone breast implants. *Plast Reconstr Surg* 1979;63:700–7.
- Wilflingseder P, Propst A, Mikuz G. Constrictive fibrosis following silicone implants in mammary augmentation. *Chir Plastica* 1974;2:215–29.
- Siggelkow W, Faridi A, Spiritus K, et al. Histological analysis of silicone breast implant capsules and correlation with capsular contracture. *Biomaterials* 2003;4:1101–9.
- Lossing C, Hansson HA. Peptide growth factors and myofibroblasts in capsules around human breast implants. *Plast Reconstr Surg* 1993;91:1277–86.
- Van Diest PJ, Beekman WH, Hage JJ. Pathology of silicone leakage from breast implants. *J Clin Pathol* 1998;51:493–7.
- Luke J, Kalassinski V, Turnicky RP, et al. Pathologic and biophysical tissue from 86 cases. *Plast Reconstr Surg* 1997;100:1558–65.
- Copeland D, Choi M, Bleiweiss JJ. Silicone breakdown and capsular synovial metaplasia in textured-wall saline breast prostheses. *Plast Reconstr Surg* 1994;94:628–33.
- Malata CM, Feldberg L, Coleman DJ, et al. Textured or smooth implants for breast augmentation? Three year follow-up of a prospective randomised controlled trial. *Br J Plast Surg* 1997;50:99–105.
- Wider TM, Yager JS, Rittenberg T, et al. The inhibition of fibroblast-populated collagen lattice contraction by human amniotic fluid: a chronological examination. *Plast Reconstr Surg* 1993;91:1287–93.
- Gabbiani G, Ryan GB, Majno G. Presence of a modified fibroblast in granulation tissue and their possible role in wound contraction. *Experientia* 1971;27:549–52.
- Baker Jr JL, Chandler ML, LeVier RR. Occurrence and activity of myofibroblasts in human capsular tissue surrounding mammary implants. *Plast Reconstr Surg* 1981;68:905–12.
- Rudolph R. Location of the force of wound contracture. *Surg Gynecol Obstet* 1979;148:547–51.
- Shin D, Minn KW. The effect of myofibroblast on contracture of hypertrophic scar. *Plast Reconstr Surg* 2004;113:633–40.
- Coleman DJ, Sharpe DT, Naylor IL, et al. The role of the contractile fibroblast in the capsules around tissue expanders and implants. *Br J Plast Surg* 1993;46:547–56.
- Heden P, Bronz G, Elberg JJ, et al. Long-term safety and effectiveness of Style 410 highly cohesive silicone breast implants. *Aesthetic Plast Surg* 2009;33:430–6.
- Burkhardt BR. Comparing contracture rates: probability theory and the unilateral contracture. *Plast Reconstr Surg* 1984;74:527–9.
- Peterson HD, Burt GB. The role of steroids in prevention of circumferential capsular scarring in augmentation mammoplasty. *Plast Reconstr Surg* 1974;54:28–30.
- Oneal RM, Argenta LC. Late side effects related to inflatable breast prostheses containing soluble steroids. *Plast Reconstr Surg* 1982;69:641–5.
- Perrin ER. The use of soluble steroids within inflatable breast prostheses. *Plast Reconstr Surg* 1981;57:163–6.
- Ellenberg AM. Marked thinning of the breast skin flaps after insertion of implants containing triamcinolone. *Plast Reconstr Surg* 1977;60:755.



29. Barker DE, Retsky MI, Shultz S. "Bleeding" of silicone from bag-gel breast implants and its clinical relation to fibrous capsule formation. *Plast Reconstr Surg* 1978;**61**:836–41.
30. Spear SL, Murphy DK, Slicton A, et al. Inamed silicone breast implant core study. results at 6 years. *Plast Reconstr Surg* 2007;**120**:85–185.
31. Rohrich RJ, Reece EM. Breast augmentation today: saline versus silicone – what are the facts? *Plast Reconstr Surg* 2008;**121**:669–72.
32. Asplund O. Capsular contracture in silicone gel and saline-filled breast implants after reconstruction. *Plast Reconstr Surg* 1984;**73**:270–5.
33. Gylbert L, Asplund O, Jurell G. Capsular contracture after breast reconstruction with silicone gel and saline-filled implants; a 6-year follow-up. *Plast Reconstr Surg* 1990;**85**:373–7.
34. McKinney P, Tresley G. Long-term comparison of patients with gel and saline mammary implants. *Plast Reconstr Surg* 1983;**72**:27–31.
35. Gutowski KA, Mesna GT, Cunningham BL. Saline-filled implants; a plastic surgery educational foundation multicenter outcome study. *Plast Reconstr Surg* 1997;**100**:1019–27.
36. Haecke P, Galsberg SB, Roth MZ, et al. The saline versus silicone breast implant debate: separating fact from fiction. *Plast Reconstr Surg* 2008;**121**:1847–9.
37. Stevens WG, Pacella SJ, Hirsch E, et al. Patient retention and replacement trends after saline breast implants: are deflations inflationary? *Aesthetic Plast Surg* 2009;**33**:54–7.
38. Macadam SA, Ho AL, Cook EF Jr., et al. Patient satisfaction and health-related quality of life following breast reconstruction: a comparison of patient-reported outcomes amongst saline and silicone implant recipients. [epub ahead of print]. doi:10.1097/PRS.0b013e3181cb5c5f8.
39. Cherup LL, Antaki JF, Liang MD, et al. Measurement of capsular contracture: the conventional breast implant and the Pittsburgh implant. *Plast Reconstr Surg* 1989;**84**:893–901.
40. Pollock H. Breast capsular contracture: a retrospective study of textured versus smooth silicone implants. *Plast Reconstr Surg* 1993;**91**:404–7.
41. Coleman DJ, Foo ITH, Sharpe DT. Textured or smooth implants for breast augmentation? A prospective controlled trial. *Br J Plast Surg* 1991;**44**:444–8.
42. Asplund O, Gylbert L, Jurell G, et al. Textured or smooth implants for submuscular breast augmentation: a controlled study. *Plast Reconstr Surg* 1996;**97**:1200–6.
43. Burkhardt BR, Demas CP. The effect of Siltex texturing and povidone-iodine irrigation on capsular contracture around saline inflatable breast implants. *Plast Reconstr Surg* 1994;**93**:129–30.
44. Fagrell D, Bergrenn A, Tarpila E. Capsular contracture around saline-filled fine textured and smooth mammary implants: a prospective 7.5-year follow-up. *Plast Reconstr Surg* 2001;**108**:2108–12.
45. Handel N, Cordray T, Gutierrez J, et al. A long-term study of outcomes, complications, and patient satisfaction with breast implants. *Plast Reconstr Surg* 2006;**117**:757–67.
46. Hakelius L, Ohlsen L. A clinical comparison of the tendency to capsular contracture between smooth and textured gel-filled silicone mammary implants. *Plast Reconstr Surg* 1992;**90**:247–54.
47. Hakelius L, Ohlsen L. Tendency to capsular contracture around smooth and textured gel-filled silicone mammary implants: a five-year follow-up. *Plast Reconstr Surg* 1997;**100**:1566–9.
48. Collis N, Coleman DJ, Foo IT, et al. Ten-year review of a prospective randomised controlled trial of textured versus smooth subglandular silicone gel breast implants. *Plast Reconstr Surg* 2000;**106**:786–91.
49. Wong CH, Samuel M, Tan BK, et al. Capsular contracture in subglandular breast augmentation with textured versus smooth breast implants; a systematic review. *Plast Reconstr Surg* 2006;**118**:1224–36.
50. Barnsley GP, Sigurdson LJ, Barnsley SE. 2006 PRS 117 2182 Textured surface breast implants in the prevention of capsular contracture among breast augmentation patients: a meta-analysis of randomized controlled trials. *Plast Reconstr Surg* 2006;**117**:2182–90.
51. Pandya AN, Dickson MG. Capsule within a capsule: an unusual entity. *Br J Plast Surg* 2002;**55**:455–6.
52. Capozzi A. Long-term complications of polyurethane-covered breast implants. *Plast Reconstr Surg* 1991;**88**:158–61.
53. Pennisi VR. Long-term use of polyurethane breast prostheses; a 14-year experience. *Plast Reconstr Surg* 1990;**86**:368–71.
54. Melmed EP. Polyurethane implants: a 6-year review of 416 patients. *Plast Reconstr Surg* 1988;**82**:285–90.
55. Hester Jr TR, Nahai F, Bostwick J, et al. A 5-year experience with the polyurethane-covered mammary prostheses for treatment of capsular contracture, primary augmentation and breast reconstruction. *Clin Plast Surg* 1988;**15**:569–85.
56. Barone FE, Perry RN, Maxwell P, et al. The biomechanical and histopathologic effects of surface texturing with silicone and polyurethane in tissue implantation and expansion. *Plast Reconstr Surg* 1992;**90**:77–86.
57. Cohny BC, Cohny TB, Hearne VA. Nineteen years experience with polyurethane foam-covered mammary prosthesis: a preliminary report. *Ann Plast Surg* 1991;**27**:27–30.
58. Hester Jr TR, Ford NF, Gale PJ, et al. Measurement of 2,4-toluenediamine in urine and serum samples from women with Mème or Replicon breast implants. *Plast Reconstr Surg* 1997;**100**:1291–8.
59. Hester Jr TR, Tebbetts JB, Maxwell GP. The polyurethane-covered mammary prosthesis: fact and fiction (II). *Clin Plast Surg* 2001;**28**:579–86.
60. Dempsey WC, Latham WD. Subpectoral implants in augmentation mammoplasty. *Plast Reconstr Surg* 1968;**42**:515–21.
61. Scully SJ. Augmentation mammoplasty without contracture. *Ann Plast Surg* 1981;**6**:262–70.
62. Pajjikos A, Deva AK, Vickery K, et al. Detection of subclinical infection in significant breast implant capsules. *Plast Reconstr Surg* 2003;**111**:1605–11.
63. Handel N, Silverstein MJ, Gamagami P, et al. Factors affecting mammographic visualization of the breast after augmentation mammoplasty. *JAMA* 1992;**269**:987–8.
64. Henriksen TF, Fryzek JP, Hölmich LR, et al. Surgical intervention and capsular contracture after breast augmentation: a prospective study of risk factors. *Ann Plast Surg* 2005;**54**:343–51.
65. Wiener TC. Relationship of incision choice to capsular contracture. *Aesthetic Plast Surg* 2008;**32**:303–6.
66. Williams C, Aston S, Rees TD. The effect of hematoma on the thickness of pseudosheaths around silicone implants. *Plast Reconstr Surg* 1975;**56**:194–8.
67. Hipps CJ, Raju DR, Straith RF. Influence of some operative and postoperative factors on capsular contracture around breast prostheses. *Plast Reconstr Surg* 1978;**61**:384–9.
68. Tebbetts JB. Achieving a predictable 24-hour return to normal activities after breast augmentation: part I. Refining practices by using motion and time study principles. *Plast Reconstr Surg* 2002;**109**:273–90.
69. Hedén P, Jernbeck J, Hober M. Breast augmentation with anatomical cohesive gel implants. *Clin Plast Surg* 2001;**28**:531–52.
70. Adams WP, Rios JL, Smith SJ. Enhancing patient outcomes in aesthetic and reconstructive breast surgery using triple antibiotic breast irrigation: six-year prospective clinical study. *Plast Reconstr Surg* 2006;**117**:30–6.
71. Cunningham B. The mentor core study on silicone MemoryGel breast implants. *Plast Reconstr Surg* 2007;**120**:195–295. discussion 305–325.

72. Courtiss EH, Goldwyn RM, Anastasi GW. The fate of breast implants with infection around them. *Plast Reconstr Surg* 1979; **63**:812–6.
73. Burkhardt BR, Dempsey PD, Schnur PL, et al. Capsular contracture: a prospective study of the effect of local antibacterial agents. *Plast Reconstr Surg* 1986; **77**:919–32.
74. Adams Jr WP, Connor WCH, Barton FE, et al. Optimizing breast-pocket irrigation: the post-Betadine era. *Plast Reconstr Surg* 2001; **107**:1596–601.
75. Virden CP, Dobke MK, Stein P, et al. Subclinical infection of the silicone breast implant surface as a possible cause of capsular contracture. *Aesthetic Plast Surg* 1992; **16**:173–9.
76. Costerton JW, Stewart PS, Greenberg EP. Bacterial biofilms: a common cause of persistent infections. *Science* 1999; **284**:1318–22.
77. Granchi D, Cavedagna D, Ciapetti G, et al. Silicone breast implants: the role of immune system on capsular contracture formation. *J Biomed Mater Res* 1995; **29**:197–202.
78. Polo M, Smith PD, Kim YJ, et al. Effect of TGF- $\alpha$ 2 on proliferative scar fibroblast kinetics. *Ann Plast Surg* 1999; **43**:185–90.
79. Kuhn A, Singh S, Smith PD. Periprosthetic breast capsules contain the fibrogenic cytokines TGF- $\beta$ 1 and TGF- $\beta$ 2, suggesting possible new treatment approaches. *Ann Plast Surg* 2000; **44**:387–91.
80. Shah M, Foreman DM, Ferguson MW. Neutralisation of TGF- $\beta$ 1 and TGF- $\beta$ 2 or exogenous addition of TGF- $\beta$ 3 to cutaneous rat wounds reduces scarring. *J Cell Sci* 1995; **108**:985–1002.
81. Choi BM, Kwak HJ, Jun CD, et al. Control of scarring in adult wounds using antisense transforming growth factor-beta1 oligodeoxynucleotides. *Immunol Cell Biol* 1996; **74**:144–50.
82. Mazaheri MK, Schultz GS, Blalock TD, et al. Role of connective tissue growth factor in breast implant elastomer capsular formation. *Ann Plast Surg* 2003; **50**:263–8.
83. Ruiz-de-Erenchun R, Dotor de las Herreiras J, Hontanilla B. Use of the transforming growth factor beta1 inhibitor peptide in periprosthetic capsular fibrosis: experimental model with tetraglycerol dipalmitate. *Plast Reconstr Surg* 2005; **116**:1370–8.
84. Ferder L, Inserra F, Romano L, et al. Decreased glomerulosclerosis in aging by angiotensin converting enzyme inhibitors. *J Am Soc Nephrol* 1994; **5**:1147–52.
85. Zimman OA, Toblli J, Stella I, et al. The effects of angiotensin-converting enzyme inhibitors on the fibrous envelope around mammary implants. *Plast Reconstr Surg* 2007; **120**:2025–33.
86. Reid RR, Greve SD, Casas LA. The effect of zafirlukast (Accolate) on early capsular contracture in the primary augmentation patient: a pilot study. *Aesthet Surg J* 2005; **25**:26–30.
87. Schlesinger SL, Ellenbogen R, Desvigne MN, et al. Zafirlukast (Accolate): a new treatment for capsular contracture. *Aesthet Surg J* 2002; **22**:329–36.
88. Gryskiewicz JM. Investigation of Accolate and Singulair for treatment of capsular contracture yields safety concerns. *Aesthet Surg J* 2003; **23**:98–102.
89. Ulrich D, Lichtenegger F, Eblenkamp M, et al. Matrix metalloproteinase's, tissue inhibitors of metalloproteinase's, aminopoterminal propeptide of procollagen type III, and hyaluronan in sera and tissue of patients with capsular contracture after augmentation with triluent breast implants. *Plast Reconstr Surg* 2004; **114**:229–36.
90. Baker JL, Jr. Classification of spherical contractures. Presented at the Aesthetic Breast Symposium Scottsdale, Arizona, 1975.
91. Spear SL, Baker Jr JL. Classification of capsular contracture after prosthetic breast reconstruction. *Plast Reconstr Surg* 1995; **96**:1119–23.
92. Stone CA. *Plastic Surgery: Facts*. London: Greenwich Medical Media Limited; 2001.
93. Gylbert L, Asplund O, Jurrell G, et al. Results of subglandular breast augmentation using a new classification method. 18-year follow up. *Scand J Plast Reconstr Surg Hand Surg* 1989; **23**:133–6.
94. Moore JR. Applanation tonometry of breasts. *Plast Reconstr Surg* 1979; **63**:9–12.
95. Netscher DT. Aesthetic outcome of breast implant removal in 85 consecutive patients. *Plast Reconstr Surg* 2004; **113**:1057–9.
96. Stevens WG, Pacella SJ, Gear AJ, et al. Clinical experience with a fourth generation textured silicone gel breast implant: a review of 1012 Mentor MemoryGel breast implants. *Aesthet Surg J* 2008; **28**:642–7.
97. Burkhardt BR. Capsular contracture: hard breasts, soft data. *Clin Plast Surg* 1988; **15**:521–32.