

The Periareolar Approach to Augmentation Mammoplasty

INTRODUCTION

The periareolar incision for augmentation mammoplasty allows for excellent, direct access with an inconspicuous scar, making this a particularly versatile approach. First described in the 1970s (1–4), this method provides central access to the implant pocket and is compatible with all planes of dissection and most types of implants (5). It is equivalent to or better than an inframammary approach at preserving nipple sensation (6,7). The nipple-areola junction appears to be a privileged area for scars; the resultant scar is often inconspicuous. In fact, in our experience, very few patients have expressed dissatisfaction with their scars. This is in contrast to our earlier experience with inframammary incisions, where dissatisfaction with scars was more common (8). The location of the periareolar incision is independent of the inframammary fold. Furthermore, it is an excellent choice when lowering of the inframammary fold is desired either at the first operation or subsequent operations (5). This incision does not interfere with breast biopsies or mastectomy incisions performed through or around the areola and is compatible with future mastopexy incisions by simply extending the periareolar incision around the entire areola (3–5,8–14). Finally, should the patient require revisionary surgery, the periareolar approach can be used again for most procedures (15).

This approach does violate some breast parenchyma and may create scarring within the breast, but in practice this is rarely a problem clinically or radiographically (9,10,12,14). A periareolar scar may be more visible than an inframammary scar in the upright patient but tends to be less visible when the patient is supine. The scar is only visible when the entire breast is exposed; otherwise the scar is hidden by even the most minimal amount of clothing. The periareolar approach can be used in virtually all women, in breasts with or without ptosis, and with most small or large areolas. As the amount of breast parenchyma increases, the periareolar incision becomes less desirable because of the increasing amount of breast tissue that must be traversed to reach the retromammary space. One concern of going through the breast near the nipple is the increased likelihood of contamination of the implant with breast bacterial flora. Such contamination has been speculated to be a risk factor for infection or capsular contracture (16).

In breast augmentation, the choice of incision must be considered along with several other decisions, including subpectoral versus subglandular pocket placement, smooth versus textured and round versus anatomic implant choice, and accompanying mastopexy or not. A periareolar incision facilitates a future mastopexy, whereas a previous inframammary incision does not help and may in fact interfere. If the patient's areola is large or the inframammary fold is high, the periareolar approach is similarly appealing. Even if the areola is small or the fold is diminutive or absent, it may be desirable to use the existing areola edge

rather than estimate the location of the incision at the site of the new fold to be created by the breast implant. In patients with minimal or no ptosis and an existing inframammary fold 4 to 6 cm below the caudal edge of the areola, the periareolar approach has no major cosmetic advantages over the inframammary incision. Although remote incision placement, such as transaxillary and transumbilical, may carry certain cosmetic advantages, in many situations it is more difficult and potentially less accurate than the periareolar approach, even with the help of an endoscope. The periareolar approach is direct, easy, and user friendly and does not require special equipment (18).

TECHNIQUE

The preoperative markings are performed with the patient facing forward, sitting or standing upright, with her arms at her sides. The breast meridian, inframammary fold, and the location of the planned inframammary fold are marked. In the operating room, before the infiltration of an epinephrine-containing local anesthetic, the periareolar incision is marked precisely at the junction of the areola and surrounding unpigmented breast skin. It is important that this be performed prior to infiltration of any local anesthetic and/or epinephrine-containing solution because these can distort or obscure this border and make it more difficult to place the skin incision correctly. The incision is placed directly inferior for most dissections (4). In general, we try to avoid making the incision above the equator of the areola, and we center the skin incision at the 6 o'clock position (13). Perioperative antibiotics are recommended as in most procedures involving prostheses, but their use is optional.

The patient is positioned in the akimbo position or with the arms abducted no more than 90 deg on padded arm boards. It is essential that the patient's shoulders be level to best judge the intraoperative result when the patient is sat upright during the operation. Adequate lighting is crucial for this procedure; use of an endoscope, headlight, lighted retractor, or lighted electrocautery is recommended.

The region to be incised is infiltrated with a local anesthetic solution containing epinephrine. After allowing adequate time for the epinephrine to take effect, the skin incision is made through the dermis with a scalpel, and electrocautery is then used to incise into the breast tissue (Fig. 111.1). Skin hooks are placed on either side of the wound to provide the necessary retraction. The dissection through the breast tissue proceeds either directly posteriorly or by beveling inferiorly toward the chest wall (13) (Fig. 111.2). This maneuver leaves adequate breast tissue caudally to facilitate wound closure and preserves the skin and the breast contour. Rake retractors followed by Army/Navy retractors are used as the dissection proceeds

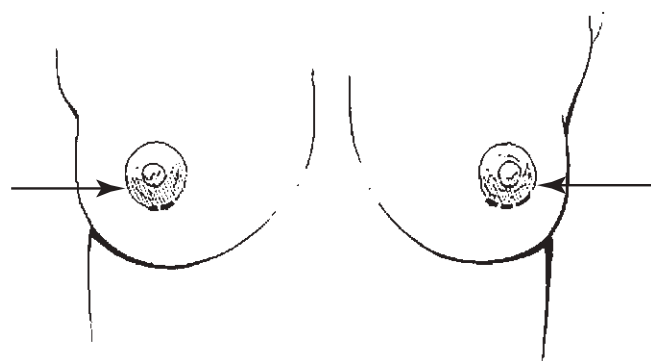


Figure 111.1. It is crucial to make the periareolar incision precisely along the edge of the areola. If done accurately, this produces a nearly invisible scar over time. The incision should be centered over the 6 o'clock position.

deeper into the breast, toward the chest wall. When the pectoralis fascia is reached, the breast tissue is mobilized off this layer, exposing the underlying fascia and muscle in an area corresponding to the lower pole of the breast from the inframammary fold inferiorly, to a point superiorly, which may vary depending on the existing skin envelope and degree of ptosis (Fig. 111.3). Inferiorly and inferolaterally, the dissection is

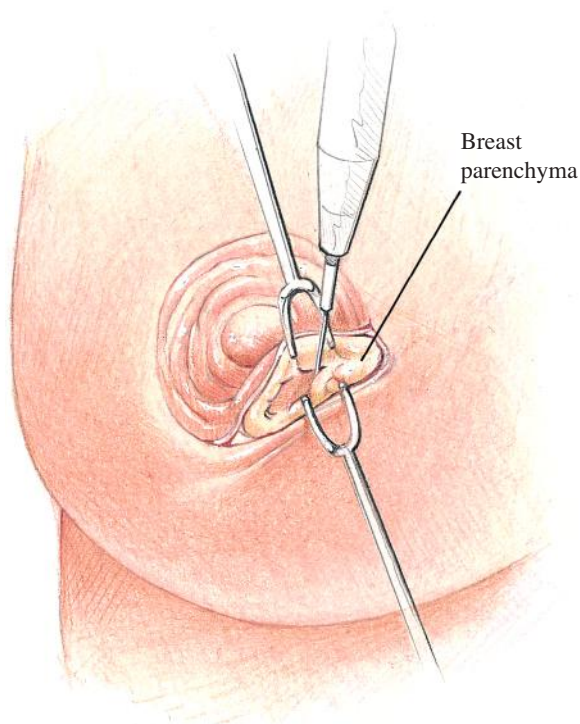


Figure 111.2. After the skin incision has been made, dissection begins with an electrocautery cutting either directly posteriorly or obliquely through the breast, aiming inferiorly while deepening the incision. For subpectoral augmentation, the dissection proceeds more medially. We recommend against an initial superficial dissection just beneath the skin, which is more likely to produce visible subcutaneous scar distortion. As the dissection deepens, it is prudent to use a scalpel or heavy, sharp scissors to completely divide the deeper aspect of the breast down to the pectoral fascia in order to create a tunnel to perform the operation.

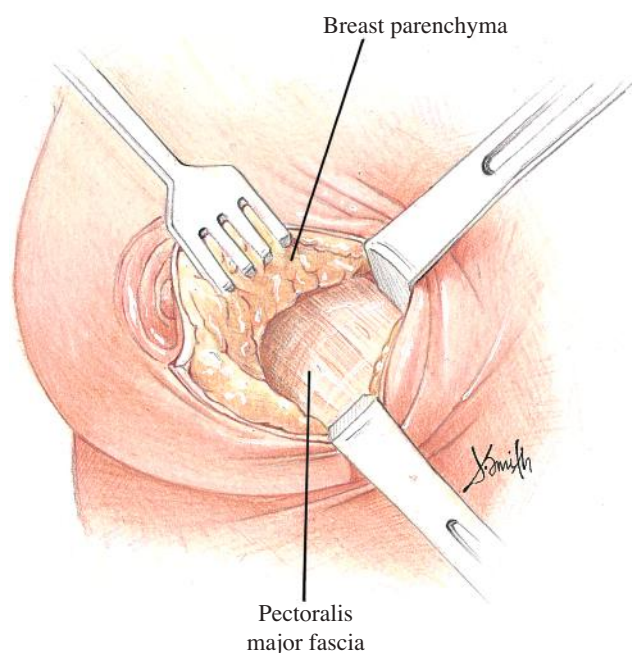


Figure 111.3. After the fascia has been identified, the breast is reflected off the underlying pectoralis major using cautery or sharp dissection. For subglandular breast augmentation, the dissection continues until the entire planned pocket has been created. A tissue expander or an inflatable implant can be used and inflated with saline or air to help with the dissection and to identify areas that need further release. For subpectoral augmentation, the breast inferior to the pectoralis muscle should be dissected first, lifting that portion of the breast off the muscle just as in a subglandular augmentation. The free inferior edge of the pectoralis muscle should be exposed to allow access beneath it.

subcutaneous down to the level of the desired inframammary fold (Fig. 111.4). If a subglandular approach is to be used, the remainder of the pocket is then precisely dissected under direct vision with electrocautery, fiber-optic lighting, or endoscopy, and Deaver retractors.

When performing a subpectoral augmentation, the inferior edge of the exposed pectoralis muscle is then grasped with an

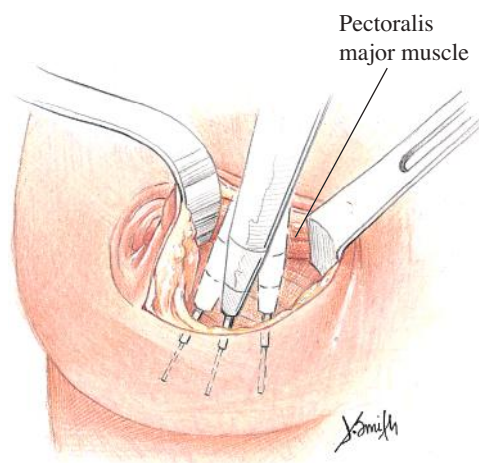


Figure 111.4. The inferior portion of the pocket should be created using primarily sharp cautery dissection under direct visualization. Subtle adjustments can then be made with blunt finger stretching and pulling or pushing movements. Anterior traction on the overlying tissues helps with these maneuvers. Subglandular dissection should proceed inferiorly down to the fold.

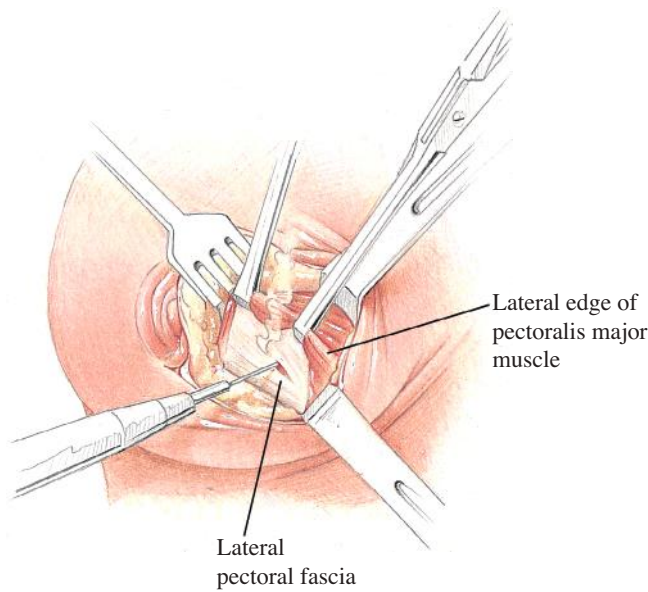


Figure 111.5. For subpectoral augmentation, the free edge of the pectoralis major muscle is grasped using one or two Allis clamps and lifted up out of the wound through the tunnel that has already been created.

Allis clamp. The lower edge of the muscle is lifted up and separated from the underlying chest wall by first creating a tunnel in the central portion of the subpectoral space. This step provides access to the subpectoral plane (Fig. 111.5). The subpectoral pocket is precisely enlarged using a combination of electrocautery and minimal blunt dissection (Fig. 111.6). Care is taken to cauterize perforating blood vessels before they are cut. Throughout this dissection, it is essential that the utmost care be taken to avoid lifting either the serratus anterior or the pectoralis minor muscles. The completed pocket is created by releasing the entire length of the lower edge of the pectoralis major muscle so it is confluent with the previously created

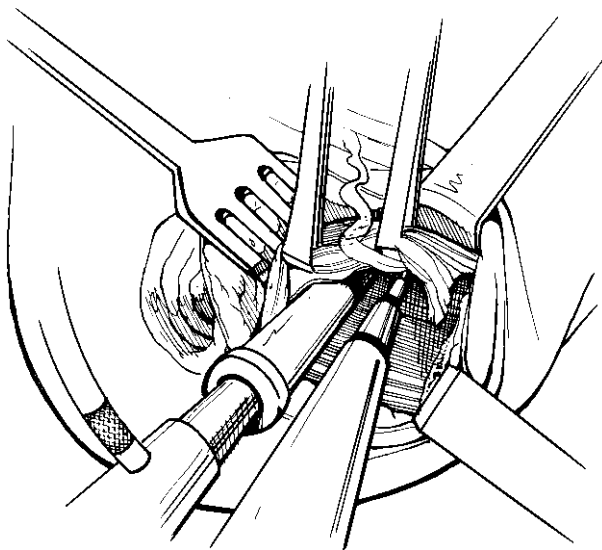


Figure 111.6. Using fiberoptic lighting or an endoscope, the muscle is sharply and carefully released using the electrocautery medially and inferiorly to create a pocket with the desired shape.

lower pole subglandular pocket. After the muscle has been completely divided along its lower border, the subglandular dissection is finalized. Hemostasis is confirmed with fiberoptic lighting and precision use of electrocautery, followed by irrigation of the wound with a triple antibiotic and/or dilute Betadine solution. The skin around the incision should then be repped and the single surgeon who will be handling the implant should don new, powder-free gloves.

In the case of inflatable implants, air is aspirated from the prostheses, and they are then rolled like a cigar from each side toward the valve and inserted into the pocket. The implants are filled with the proper amount of saline or other fluid, and with the fill tubes left in, the incision is tacked together with skin staples and the patient is placed in the sitting position. The breasts are assessed for symmetry in terms of size, position, contour, inframammary fold, and nipple height.

After the surgeon is satisfied, the fill tubes are removed, and valve closure is verified under direct vision. The breast gland is then repaired with several interrupted 2-0 or 3-0 PDS sutures on a taper needle. A 3-0 or 4-0 absorbable monofilament suture is then used for buried, interrupted dermal sutures. Finally, a 3-0 or 4-0 absorbable monofilament suture is used for a running intradermal closure. External tissue glue is then applied to the wound as a surface dressing (14).

DISCUSSION

The periareolar approach works well with all types of implants: silicone or inflatable, round or anatomic, textured or smooth. Because of its excellent versatility and exposure, it often can adequately accommodate anatomic implants. The use of inflatable implants allows the effective use of a periareolar incision, even with the smallest of areola. Even in a small areola of 25 mm diameter, a semicircular incision around the areola measures approximately 4 cm in length (10) (Figs. 111.7 to 111.9). It is the logical choice when eventual mastopexy is suspected but is

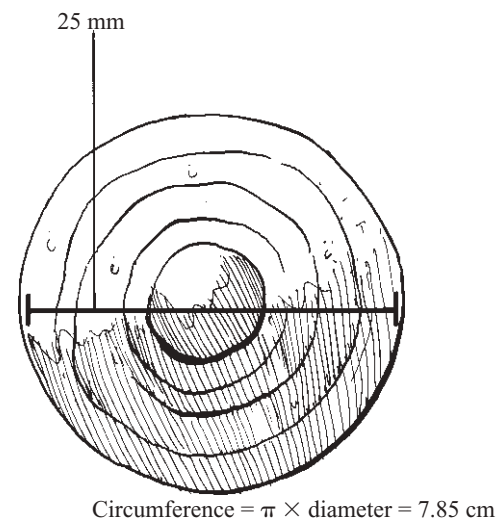


Figure 111.7. Although there are legitimate drawbacks to all incisions, including the periareolar one, this approach does not limit the size of incision, even in patients with a small areola. Even with an areola measuring 25 mm (about the size of a quarter), this allows the easy creation of a 4-cm incision along one half of the areola circumference.

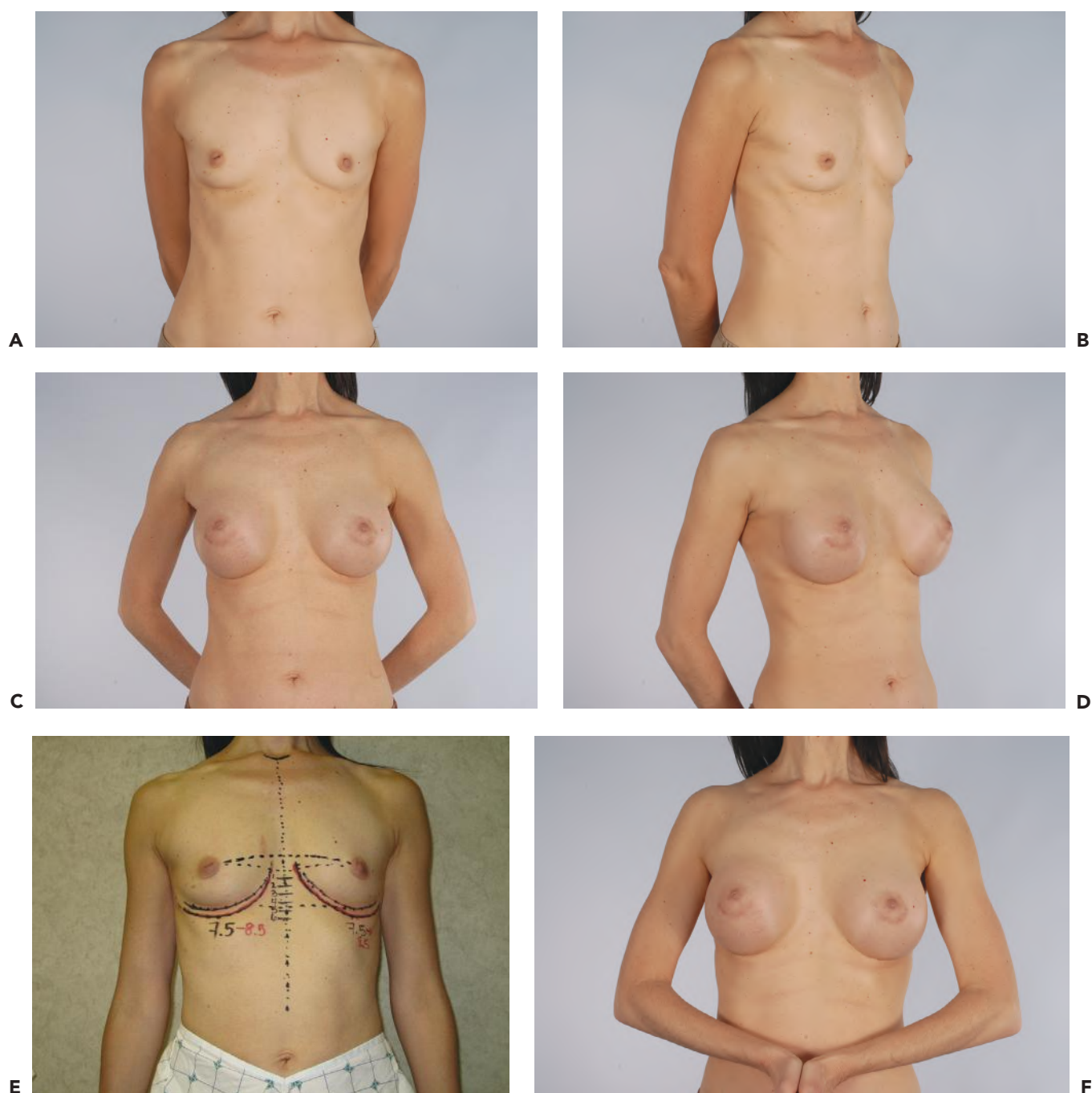

Figure 111.8. A, B: A 51-year-old, 5'7" tall woman before breast augmentation. C, D: The same patient 3 months after augmentation mammoplasty with a 375-mL silicone gel implant placed in a dual-plane pocket through a periareolar incision. E: Preoperative markings. Note that the inframammary fold is lowered from 7.5 cm to 8.5 cm. F: Patient at 3 months postop flexing her pectoral muscles to show her level of animation deformity.

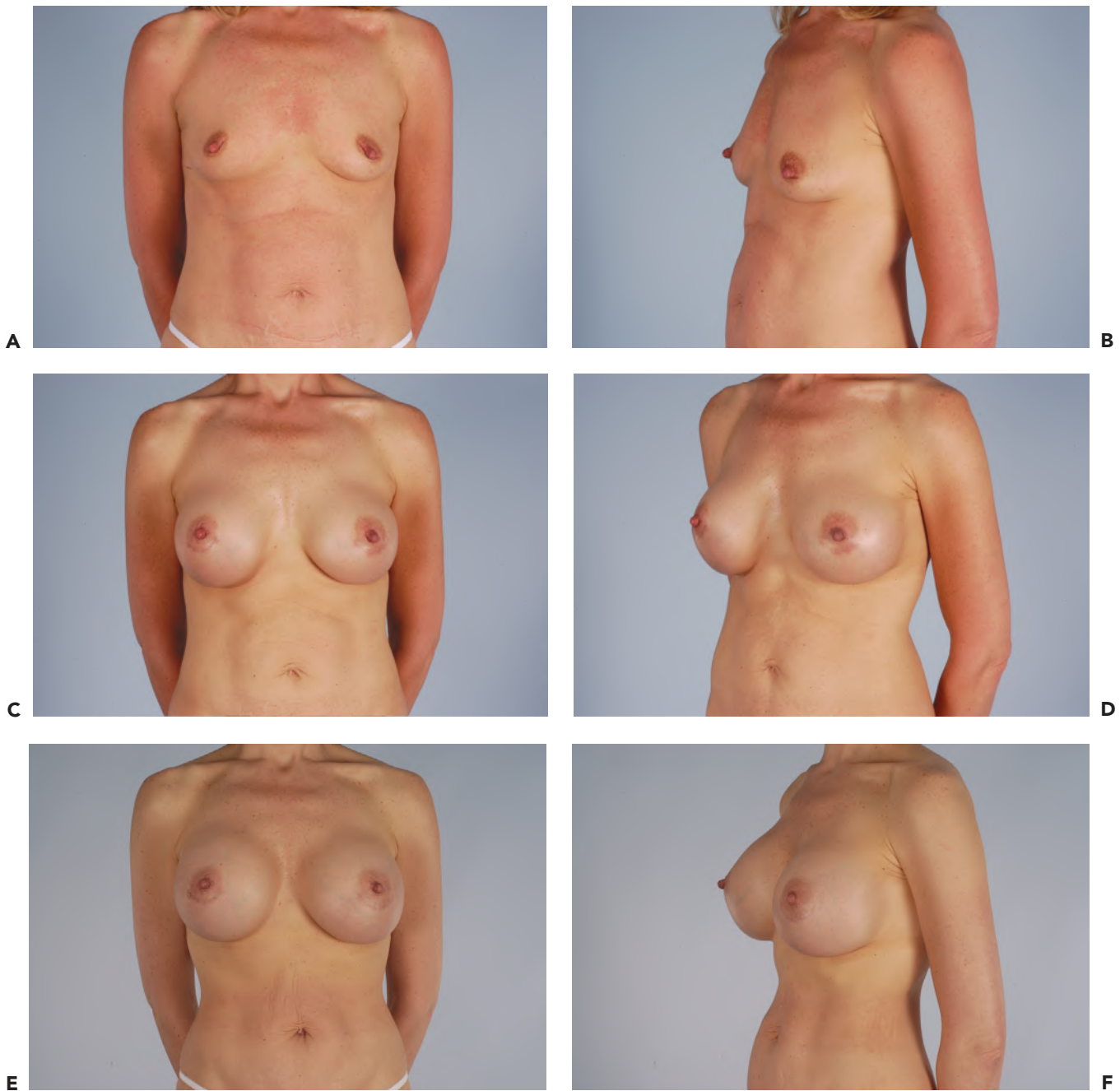

Figure 111.9. A, B: A 41-year-old, 5'10" tall woman before breast augmentation. C, D: The same patient 6 months after augmentation mammoplasty with a 425-mL high-profile, saline-filled implant placed in a dual-plane pocket through a periareolar approach. E, F: The same patient 3 months after bilateral implant exchange to a 700-mL high-profile, saline-filled implant placed in a dual-plane pocket through a periareolar approach.

not certain preoperatively (5). This approach is also the best in cases of tubular breast hypomastia because it affords the possibility of periareolar skin or breast parenchymal excision, if necessary (5). Secondary procedures requiring capsulectomy, implant exchange, unilateral augmentation for symmetry, pocket size adjustments, and correction of implant malposition can all be performed through the periareolar incision.

EDITORIAL COMMENTS

The periareolar incision frequently provides good access to the subglandular or subpectoral plane. In my practice this approach is limited to women with a large areolar diameter. It is also recommended for women with a tuberous breast contour or when the inframammary fold needs to be lowered. One limitation of this approach is that it may be difficult to insert prefilled silicone gel devices through these sometimes-limited-length incisions. It is my preference to use an inframammary approach when inserting prefilled devices that are greater than 400 cc. As mentioned in the chapter, the dissection can proceed directly through the parenchyma or through the subcutaneous plane along the lower pole of the breast. Bacterial translocation can be a concern following the parenchymal approach, and this may predispose toward capsular contracture. When this approach is used, women are routinely placed on oral antibiotics for 1 week. Studies comparing periareolar versus inframammary approach have demonstrated a higher incidence of capsular contracture (16). However, this is minimized when the devices are placed in the subpectoral position (19). Studies comparing sensitivity of the nipple-areolar complex have demonstrated no significant difference between the periareolar and inframammary approaches (7).

REFERENCES

1. Williams JE. Experiences with a large series of silastic breast implants. *Plast Reconstr Surg* 1972;49:253.
2. Jenny H. Areolar approach to augmentation mammoplasty. *Plast Reconstr Surg* 1974;53:344.
3. Jones FR, Tauras AP. A periareolar incision for augmentation mammoplasty. *Plast Reconstr Surg* 1973;51:641.
4. Gruber R, Friedman GD. Periareolar subpectoral augmentation mammoplasty. *Plast Reconstr Surg* 1981;67:453.
5. Hidalgo DA. Breast augmentation: choosing the optimal incision, implant, and pocket plane. *Plast Reconstr Surg* 2000;105(6):2202-2216.
6. Okwueze MI, Spear ME, Zwyghuizen AM, et al. Effect of augmentation mammoplasty on breast sensation. *Plast Reconstr Surg* 2006;117:73-83.
7. Mofid MM, Klatsky SA, Singh NK, et al. Nipple-areola complex sensitivity after primary breast augmentation: a comparison of periareolar and inframammary incision approaches. *Plast Reconstr Surg* 2006;117:1694-1698.
8. Becker H. The intra-areolar incision for breast augmentation. *Ann Plast Surg* 1999;42(1):103-106.
9. Biggs TM, Humphreys DH. Augmentation mammoplasty. In: Smith JW, Aston SJ, eds. *Grabb and Smith's Plastic Surgery*. 4th ed. Boston: Little, Brown; 1991:1145-1156.
10. Spear SL, Matsuba H, Little JW. The medial periareolar approach to submuscular augmentation mammoplasty under local anesthesia. *Plast Reconstr Surg* 1989;84:399.
11. Riefkohl R. Augmentation mammoplasty. In: McCarthy JG, ed. *Plastic Surgery*. Vol. 6. Philadelphia: Harcourt Brace; 1990:3879-3844.
12. Biggs TM, Cukier J, Worthing JF. Augmentation mammoplasty: a review of 18 years. *Plast Reconstr Surg* 1982;69:445.
13. Spear SL, Bulan EJ. The medial periareolar approach to submuscular augmentation mammoplasty under local anesthesia: a 10 year follow up. *Plast Reconstr Surg* 2001;108(3):771-775.
14. Courtiss EH, Goldwyn RM. Breast sensation before and after plastic surgery. *Plast Reconstr Surg* 1979;58:1.
15. Hammond D. The periareolar approach to breast augmentation. *Clin Plast Surg* 2009;36(1):45-48.
16. Wiener TC. Relationship of incision choice to capsular contracture. *Aesthet Plast Surg* 2008;32:303-306.
17. Mladick RA. Breast augmentation: ease of dissection with the periareolar technique. *Aesthet Surg J* 1999;19(2):162-164.
18. Yavuzer R, Basterzi Y, Tuncer S. Using tissue adhesives for closure of periareolar incisions in breast reduction surgery. *Plast Reconstr Surg* 2003;112:337.
19. Hendricks H. Complete submuscular breast augmentation: 650 cases managed using an alternative surgical technique. *Aesthet Plast Surg*. 2007;31:147-153.