

*Title of the article:*

**Fat injection to the breasts: cosmetic augmentation, implant replacement, inborn deformity, and reconstruction after mastectomy**

*Authors:*

Kotaro Yoshimura, M.D.,<sup>1</sup> Yuko Asano, M.D.<sup>2</sup>

*Affiliations:*

<sup>1</sup> Department of Plastic Surgery, University of Tokyo School of Medicine;  
7-3-1 Hongo, Bunkyo-ku, Tokyo 113-8655, Japan

<sup>2</sup> Cellport Clinic Yokohama;

Yokohama Excellent III Building 2F, 3-35, Minami-nakadori, Naka-ku, Yokohama,  
Kanagawa 231-0006, Japan

*Corresponding author:*

Kotaro Yoshimura, M.D.

Department of Plastic Surgery, University of Tokyo School of Medicine;  
7-3-1 Hongo, Bunkyo-ku, Tokyo 113-8655, Japan

Telephone: +81-3-5800-8948; Fax: +81-3-5800-8947

E-mail: yoshimura-pla@h.u-tokyo.ac.jp

**Summary/Key points**

- Moderate augmentation (100-200 ml) of the breast is successfully achieved by autologous lipoinjection without major complications if appropriately performed in selected patients.
- Breasts augmented with fat injection are soft and show natural texture and appearance, and patients are free from daily stress and future concerns derived from foreign materials (such as complications and potential implant replacement or removal).
- Surviving fat volume varies substantially among patients, and multiple factors are likely to affect the clinical results; patient factors include skin redundancy of the breast, quality (such as viability and progenitor richness) of fat grafts, and infiltration techniques are key determinants to clinical results of lipoinjection.
- Aspirated fat tissue should be appropriately harvested and stored, and quickly processed and infiltrated with proper devices to avoid degradation of the graft tissues and to place aliquots of fat grafts as diffusely as possible.
- Relative deficiency of adipose progenitor cells in aspirated fat tissue may lead to long-term atrophy of the grafts, and supplementation of vascular stromal fraction containing adipose progenitor cells may boost the efficacy and safety of lipoinjection to the breasts.

## **I. Introduction**

Autologous fat transplantation is one of the promising cosmetic treatments for facial rejuvenation and soft-tissue augmentation due to the lack of incisional scar and complications associated with foreign materials. However, certain problems remain, such as unpredictability and a low rate of graft survival due to partial necrosis. It has also been used in breast augmentation by a limited number of plastic surgeons [1], although the use of autologous fat for breast augmentation has been controversial due to the lack of consensus on whether it is safe and appropriate because of microcalcifications that may cause confusion in the evaluation of mammograms.

Implantation of prostheses has been a golden standard for breast augmentation, but complications with artificial materials such as capsular contracture remain to be resolved. The presence of the implant and capsules induced by implants could also affect breast tissue visualization in the mammogram [2]. Furthermore, there is potential for rupture when pressure is exerted on the implant during mammography, and for this reason, hospitals in Japan reject women with breast implants to undergo mammography as a part of annual social health examinations. Recently, autologous fat injection has been re-evaluated as a potential alternative to artificial implants for breast augmentation [1,3]. This re-evaluation may reflect recent advances in autologous fat transfer and the radiological detection of breast cancer.

In this chapter, potentials of fat injection for breast augmentation or reconstruction are discussed as well as our novel approach of autologous fat grafting called cell-assisted lipotransfer (CAL) [3,4], which is concurrent transplantation of aspirated fat tissue and adipose progenitor cells.

## **II. Patient selections**

There seems to be several patient factors which may affect the clinical result of conventional lipoinjection or CAL; skin redundancy of the breasts, age, BMI, personal quality or character of fat tissue, adhesive scars, breast implant and its capsule, systemic disease such as autoimmune disease, oral corticosteroid, etc [3,5]. Good candidates are those who have sufficient fat at donor sites and the redundant breast skin with healthy vascularity and without any scars.

Lipoinjection can be performed in any patients from teens to seventies, but patients with small BMI (less than 17) or athletes with little body fat are not good candidates due to difficulty in harvesting a large volume of fat tissue. Patients, who want a large-volume (250-400 ml) augmentation, are not good candidates because augmentation volume achieved by a single session of lipoinjection is limited (100-200 ml).

Some patients are concerned about complications derived from foreign bodies and about possible surgical removal or replacement of implants in the future. Others do not want their history of breast surgery to come out. These patients want to avoid breast implants and do not usually persist in size of breast augmentation; they are one of good candidates for this procedure.

## **III. Indications**

Operative indications are described below according to three kinds of graft tissue preparations or operative purposes.

## **1) Graft tissue preparations**

As for lipoinjection, we have a conventional lipoinjection (micro-fat grafting) and a new technique; grafting of progenitor-enriched adipose tissue. We call the latter cell-assisted lipotransfer (CAL); the concept and details of CAL is described later. There are two types of CAL, mini-CAL and full-CAL; only a fluid portion of liposuction aspirates are used for harvest of adipose progenitor cells in the mini-CAL, while another similar volume of liposuction aspirates to graft tissues are used for the cell isolation in the full-CAL (Fig. 1). Thus, full-CAL requires a twice volume of adipose tissue as the conventional lipoinjection or mini-CAL; approximately 700-800 ml lipoaspirates are needed for conventional lipoinjection or mini-CAL for both breasts, while 1200-1500 ml lipoaspirates are required for the full-CAL procedure.

If BMI is less than 18 or body weight is less than 45 kg, conventional lipoinjection or mini-CAL is recommended. On the other hand, for patients with BMI over 25, full-CAL is easily performed without concerns on her donor site.

## **2) Operative purposes**

### *A) Breast augmentation*

Lipoinjection can be performed without combining any procedures. We, however, also propose a secondary lipoinjection after one-year implantation of breast prostheses if patients are very thin, have flat breasts and tight breast skin, because only a less volume lipoinjection can be performed in those cases due to high internal pressure and skin tension after injection.

### *B) Breast implant replacement*

Lipoinjection can be performed at the same time with implant removal. The implants have to be removed through a peri-areolar incision, though they can be removed through an axillary incision if lipoinjection is performed separately from implant removal.

### *C) Breast reconstruction*

Lipoinjection can be performed in any cases, but detailed assessment of tissue and skin conditions of the breasts is necessary before application. In most reconstruction cases with skin shortage, lipoinjection after tissue expansion is recommended; lipoinjection can be performed immediately after removal of the tissue expander. For patients who have sufficiently redundant skin and do not have severe scar tissue or adhesion of the skin to the underlying fascia or any other deep tissues, lipoinjection alone may successfully work. Lipoinjection can be applied to patients with the irradiated skin, though the injection volume is usually limited. A few or several sessions of lipoinjection can be performed to the irradiated breasts with each interval of more than 12 months. Lipoinjection after tissue expansion is also applied to those irradiated patients, but expander implantation under the pectoralis major muscle and a careful expansion are recommended.

### *D) Inborn deformity*

Simply hypoplastic breasts can be successfully treated with lipoinjection in most cases, but tubular deformity is hard to be improved by lipoinjection alone. Funnel chest can be corrected with lipoinjection, though the filling volume by a single surgery is limited and repetitive treatments are usually recommended.

#### **IV. Injection of progenitor-enriched fat tissue: principles and therapeutic concepts of cell-assisted lipotransfer (CAL)**

##### **1) Cell components of adipose tissue**

Adipose tissue consists predominantly of adipocytes, adipose stromal cells (ASCs), vascular endothelial cells, pericytes, fibroblasts and extracellular matrix [6]. Adipocytes constitute more than 90% of tissue volume, but they are much larger in size than other cells above and the number of adipocytes is estimated to be less than 50% [7] (Fig. 2). ASCs are considered to be adipose tissue-specific progenitor cells (adipogenic and angiogenic progenitors), a part of which have been shown to differentiate into multiple lineages and are now called adipose-derived stem cells [8]. ASCs contribute to adipose tissue turnover (adipose tissue is considered to turn over every 2-10 years [9,10]) and provide cells in next generation. ASCs are currently being used in various clinical trials, including treatments for rectovaginal fistula (autologous cultured ASCs) [11] and graft-versus-host disease (non-autologous ASCs) [12]. If ASCs are harvested from a large volume (e.g. 500 ml) of liposuction aspirates, ASCs can be used clinically without cell expansion because a sufficient number of cells can be obtained. The use of minimally manipulated fresh cells may lead to higher safety and efficacy in actual treatments.

##### **2) Aspirated fat tissue vs. intact fat tissue**

We can use aspirated fat tissue as lipoinjection material but not excised fat tissue. Aspirated fat is fragile parts of the adipose tissue taken with negative pressure. Our research revealed that aspirated fat tissue contains only a half number of ASCs compared to intact fat tissue [4] (Fig. 3). The two main reasons for this relative deficiency of ASCs contained in aspirated fat tissue are 1) a major portion of ASCs are located around large vessels (within tunica adventitia) and left in the donor tissue, and 2) a part of ASCs are released into the fluid portion of liposuction aspirates [6]. Our histological study indicated that ASCs located not only between adipocytes but also around vessels. Large-sized vessels are located in the fibrous part of the tissue, which intact fat tissue but not aspirated fat tissue contains. Thus, aspirated fat tissue is regarded as relatively progenitor-poor fat tissue compared to intact fat tissue [4].

##### **3) Stromal vascular fraction (SVF)**

Through collagenase digestion, heterogeneous cell mixture which contains any other cell types than adipocytes can be extracted from adipose tissue as a cell pellet. The cell fraction is called "stromal vascular fraction (SVF)" (Fig. 4), because they are basically stromal cells and contain vascular endothelial and mural cells. In clinical setting, SVF contains a substantial amount of blood-derived cells such as leucocytes and erythrocytes as well as adipose-derived cells such as ASCs and vascular endothelial cells [6]. Our study revealed that nucleate cells contained in SVF are composed of 37% of leucocytes, 35% of ASCs, 15% of endothelial cells and other cells, though the percentage of blood-derived cells strongly depends on individual hemorrhage volume [7]. In CAL, the freshly isolated autologous SVF is used as a supplementation for fat graft tissue without any manipulations such as cell sorting or cell culture [3,5].

#### **4) Concept of Cell-Assisted Lipotransfer (CAL)**

Aspirated fat tissue has a significantly lower progenitor/mature-cell ratio as mentioned above, and this low ASC/adipocyte ratio may be the main reason for long-term atrophy of transplanted adipose tissue. There are at least three experimental studies including ours [4,13,14], demonstrating that supplementation of adipose progenitor cells enhances the volume or weight of surviving adipose tissue. Enrichment of adipose progenitor cells by supplementation of SVF improves progenitor/adipocyte ratio; progenitor-poor aspirated fat tissue will be converted to progenitor-rich fat tissue. In CAL, freshly isolated SVF, which contains ASCs, is supplemented to progenitor-poor aspirated fat tissue; the cells are attached to the aspirated fat with the fat acting as a living bioscaffold before transplantation (Fig. 5).

Transplanted adipose tissue encounters ischemia and subsequent reperfusion as well as high internal pressure by edema and inflammatory changes in the host tissue. The microenvironments, injury-associated growth factors, and inflammation-associated cytokines and chemokines would influence on ASC behaviors during the acute phase of tissue repair [15]. Adipose grafts undergo adipocyte and capillary remodeling, and ASCs are a main cell population functioning in the repairing process of the adipose tissue [15]. The relative deficiency of ASCs in aspirated fat tissue may affect the replacement process and lead to post-operative atrophy of grafted fat, which is known to commonly occur during the first 6 months after lipoinjection.

### **V. Operative technique**

#### **1) Surgical procedures**

##### *A) Basic breast augmentation*

Donor sites are usually the thighs alone or the thighs and the abdomen or flanks, decided according to patient's preference and BMI. After the liposuction site is infiltrated with saline solution with epinephrine (0.001%) under general anesthesia, adipose tissue is suctioned using a cannula with 2.5-mm inner diameter and a conventional liposuction machine. The lipoaspirates are centrifuged at 700 g for 3 min, and put into a metal jar (1,000 ml) which is placed in water with crushed ice.

For the injection syringe, a 10 cc LeVein™ inflator (Boston Scientific Corp., MA) or our original syringe (20 ml) is used because they are screw-type syringes (with a threaded plunger) and threaded connections that fit both the connecting tube and the needle, to allow for precise control during injection (Fig. 6). To reduce the time of the procedure, two syringes are used; while one syringe is being used for an injection, the other is filled with the graft material in preparation for the next injection. A 16 or 18-gauge needle (150 mm long) is used for lipoinjection and inserted subcutaneously from inflammary fold or areolar margin (Fig. 7). The operator takes care to insert and place the needle horizontally (parallel to the body), in order to avoid damaging the pleura and causing a pneumothorax. The needle is inserted in several layers and directions, and is continuously and gradually retracted as the plunger is advanced (Fig. 7). This technique is used to obtain a diffuse distribution of the graft material. The grafts are placed into the fatty layers on, around, and under the mammary glands (but not intentionally into the mammary glands), and also into the pectoralis muscles. After training, it is not hard for an operator to

recognize the mammary gland or pectoralis fascia as a harder tissue than the fat or muscle tissue. Injection is discontinued when the skin tension becomes tense; average volume of injection is 250-300 ml for each breast.

#### *B) Breast implant replacement*

For patients with implants, lipoinjection can be performed simultaneously with implant removal. Breast implants are removed through a periareolar incision, which is placed at a caudal third of the areola margin. The lipoinjection is begun at the deepest layer under the implant capsule and completed with the injection into the most superficial subcutaneous layer. In the deepest layer, the operator takes care to insert and place the needle horizontally (parallel to the body), in order to avoid damaging the pleura and causing a pneumothorax, by inserting the operator's finger into the implant capsule, placing it on the bottom of the capsule, and recognizing the location of the injection needle (Fig. 8). The needle is inserted from the lateral margin of the breast and from the inframammary fold. Injection into the mammary glands or into the capsular cavity is not performed. Finally, the capsular cavity is washed with saline and the periareolar incision is closed.

#### *C) Breast reconstruction*

For breast reconstruction, lipoinjection is performed basically similar to basic breast augmentation. Centrifuged lipoaspirates are injected from the inframammary fold or scars. In cases who have substantial scar tissues or adhesion between skin and deep tissues, tissue expander is inserted first and breast reconstruction with lipoinjection is performed as a secondary surgery immediately after removal of the tissue expander. The volume of injection is usually determined by skin tension of the reconstructed breast.

## **2) Preparation procedures of graft materials**

### *A) Conventional lipoinjection*

A needed volume of lipoaspirates is harvested by liposuction and centrifuged at 700 g for 3 min, and put into a metal jar (1,000 ml) which is placed in water with crushed ice. As the centrifugation reduces the adipose volume by 25-30%, the volume reduction should be taken into account in tissue harvesting.

### *B) Full-CAL*

In full-CAL, about twice volume of lipoaspirates is harvested and a half of adipose portion and all of fluid portion of liposuction aspirates are used for isolation of SVF (Fig. 1). If a patient has  $25 <$  of BMI, 1,500 ml of aspirated fat tissue can be easily harvested from the abdomen and flanks or thighs. If BMI is less than 20, fat should be usually taken from both the abdomen and thighs.

About a half of the collected liposuction aspirate (500-700 ml of aspirated fat tissue) is used for harvest of SVF. The SVF is isolated as described below and the cell processing procedure takes about 80 min. During the processing period, the other half of lipoaspirates is harvested and prepared as a graft material with centrifugation at 700g for 3 min. The freshly isolated SVF was added to the centrifuged fat tissue, followed by gentle mixing and a 10-15 min incubation to achieve appropriate cell adhesion to the centrifuged fat tissue.

### *C) Mini-CAL*

In mini-CAL, the same volume of lipoaspirates is harvested as a conventional lipoinjection; the adipose portion is centrifuged as graft materials, while the fluid portion of liposuction aspirates is used for isolation of SVF. The cell processing process takes about 30 min. The freshly isolated SVF is added to the centrifuged fat tissue, followed by gentle mixing and a 10-15 min incubation to achieve appropriate cell adhesion to the centrifuged fat tissue.

### **3) Cell isolation procedure (Cell processing for SVF isolation)**

Processed lipoaspirate cells (PLA) cells and liposuction aspirate fluid (LAF) cells, both are so-called SVF, are separated from the fatty and fluid portions of liposuction aspirates, respectively. Both cells are used for full-CAL, while only LAF cells are used for mini-CAL (Fig. 1).

For PLA cells, the suctioned fat is digested with 0.075% collagenase in phosphate buffered saline for 30 min on a shaker at 37°C after centrifugation. Mature adipocytes and connective tissues are separated from cell pellets by centrifugation (800g, 10 min). Pellets were resuspended in erythrocyte lysis buffer (155 mM NH<sub>4</sub>Cl, 10 mM, KHCO<sub>3</sub>, 0.1 mM EDTA) and incubated for 5 min at room temperature. The pellets are resuspended and passed through a 100-mm mesh filter. To eliminate remaining collagenase, the cells pellets are repeatedly washed with resuspending in Dulbecco's modified Eagle's medium (DMEM) and following centrifugation at least three times. For LAF cells, the suctioned fluid is centrifuged (400g, 10 min), and the pellets are resuspended in erythrocyte lysis buffer. After 5 min incubation at room temperature, lysates were passed through a 100-mm mesh filter. The cell pellets are repeatedly washed with resuspending in DMEM and following centrifugation at least three times, and passed through a 100-mm mesh filter.

The whole procedure should be performed by well-trained physicians or technicians in an aseptic room (preferably at a level of good manufacturing practice) according to a designated standard operating procedure. Isolated cells should be strictly evaluated in quantity and quality. Cell counts for erythrocytes and nucleated cells are performed using a cell counter for blood test. The whole process of cell isolation takes about 80 minutes. It is also recommended that a fraction of the isolated SVF is seeded and cultured to make sure of cell viability and another fraction is frozen and stored in a deep freezer or liquid nitrogen for a future cell tracing.

## **VI. Pitfalls and how to correct**

### **1) Pre- and post-operative evaluations**

For evaluation of clinical results, physical measurements (maximum and bottom breast circumferences, etc.), mammogram, MRI, echogram, photograph, and videograph are performed. We also adopted a 3-dimensional measurement system which enables a volumetric evaluation of the breast mound in a standing position (Fig. 9). Echogram is easy to perform at every patient's visit and sensitive enough to detect small cyst formation. Long follow up with annual mammogram is recommended to detect abnormal signs such as calcification.

### **2) Clinical results**



Total operation period is approximately 2-2.5 hours for conventional lipoinjection, 2.5-3 hours for mini-CAL, and 3.5-4 hours for full-CAL. The time of the injection process ranges from 35 to 60 min for both breasts. Subcutaneous bleeding and edema is usually seen on some parts of the breasts, and resolved in one to two weeks. Transplanted adipose tissue is gradually absorbed during the first 2 postoperative months (especially during the first month), and the breast volume showed a minimal change thereafter, though skin tension sometimes becomes looser between 2 and 6 months. The 3-dimensional measurements showed that the surviving fat volume in full-CAL ranged from 100 to 250 ml at 12 months, meaning that the graft take ranged from approximately 40% to 80% (Fig. 10). Compared to breast augmentation with implants of the same size, augmentation with lipoinjection showed a lower height but more natural contour of breasts. Cyst formation depends on the volume and distribution of fat grafts. No cysts are palpable as far as injection was appropriately performed (see below), though cysts with a size of less than 5mm may be detected by echogram. Patients are generally satisfied with the resulting texture, softness, contour and absence of foreign materials despite the limited size increase possible with autologous tissue. CT scans and MRI show that transplanted fat tissue survives well and forms a significant thickness of the fatty layer not only subcutaneously on and around the mammary glands but also between the mammary glands and the pectoralis muscles.

### **3) Refinement of autologous fat graft techniques**

Surviving fat volume varies substantially among patients, and multiple factors are likely to affect the clinical results; patient factors include skin redundancy of the breast and technical factors include devices, graft fat preparation, and injection techniques. It is well accepted that adipose tissue should be placed as small aliquots, preferably within an area 3 mm in diameter. Since it takes a long time to perform ideally diffuse placement of suctioned fat in breasts [1], we use a disposable syringe with a threaded plunger and connections and a very long needle (150 mm); these devices are critical to performing large-volume lipoinjection safely and precisely in a short time [3] (Fig. 6). We use a relatively large-sized suction cannula (2.5-3.5 mm of inner diameter), centrifuge the aspirated fat, and keep it cooled until transplantation. It should be also noted that aspirated fat tissue should be injected as soon as possible, such as within 60 min after harvest. In our experience, clinical results (increase in breast size) appeared to be superior when centrifuged fat was used compared to non-centrifuged fat. This may be due to the improved adipocyte density and ASC/adipocytes ratio after centrifugation [16]. ASC supplementation dramatically improves ASC/adipocyte ratio and is suggested to minimize adipose atrophy after transplantation, though further studies are needed to elucidate the effects of ASCs.

### **4) Complications**

If injection was performed inappropriately, problems derived from fat necrosis would be seen such as no augmentation effects, cyst formation, fibrogenesis, and calcification. Small cysts (< 8 mm) detected by echogram usually disappear between 9 and 18 months, so no treatment is needed. Tiny calcifications may occur 1-2 years after surgery but they are very rare and easy to distinguish from malignant signs. To record

them as mammogram is important and useful to distinguish from abnormal changes in the future. A larger volume of liposuction could induce postoperative donor site problems such as irregularity or seroma, which are more susceptible in lean patients, so that preoperative selection of patients and careful procedures in liposuction are desirable.

#### **5) Representative cases**

Representative cases were demonstrated in Figures 11-15; one case from each category (breast augmentation with conventional lipoinjection, breast augmentation with full-CAL, breast implant replacement with full-CAL, inborn breast deformity treated with full-CAL and breast reconstruction with full-CAL).

**VII. Post-operative care**

After the surgery, the breasts should be kept in a proper position with a proper-sized brassier. Patients can take a shower on the next day. Massage of the breasts is prohibited during the first 3 months.

**VIII. Conclusions**

Increase in size obtained by lipoinjection is moderate, but patients can achieve soft and natural-looking breasts without any future concerns associated with foreign body. Major complications are not seen as far as the infiltration technique is appropriate. Our preliminary experiences of CAL technique suggested the efficacy and safety of the ASC supplementation. Through further improvements of the technique and longer follow-up studies, autologous tissue transfer may become widely used for augmentation and reconstruction of the breasts in the future.

## References

1. Coleman SR, Saboeiro AP (2007) Fat grafting to the breast revisited: safety and efficacy. *Plast Reconstr Surg* 119: 775-785
2. Tuli R, Flynn RA, Brill KL, Sabol JL, Usuki KY, Rosenberg AL. (2006) Diagnosis, treatment, and management of breast cancer in previously augmented women. *Breast J* 12: 343-348
3. Yoshimura K, Sato K, Aoi N, Kurita M, Hirohi T, Harii K (2008) Cell-assisted lipotransfer (CAL) for cosmetic breast augmentation -supportive use of adipose-derived stem/stromal cells-. *Aesthetic Plast Surg* 32: 48-55
4. Matsumoto D, Sato K, Gonda K, Takaki Y, Shigeura T, Sato T, Aiba-Kojima E, Iizuka F, Inoue K, Suga H, Yoshimura K (2006) Cell-assisted lipotransfer: supportive use of human adipose-derived cells for soft tissue augmentation with lipoinjection. *Tissue Eng* 12: 3375-3382
5. Yoshimura K, Sato K, Aoi N, Kurita M, Inoue K, Suga H, Eto H, Kato H, Hirohi T, Harii K (2008) Cell-assisted lipotransfer for facial lipoatrophy: efficacy of clinical use of adipose-derived stem cells. *Dermatol Surg* 34: 1178-1185
6. Yoshimura K, Shigeura T, Matsumoto D, Sato T, Takaki Y, Aiba-Kojima E, Sato K, Inoue K, Nagase T, Koshima I, Gonda K (2006) Characterization of freshly isolated and cultured cells derived from the fatty and fluid portions of liposuction aspirates. *J Cell Physiol* 208: 64-76
7. Suga H, Matsumoto D, Inoue K, Shigeura T, Eto H, Aoi N, Kato H, Abe H, Yoshimura K (2008) Numerical measurement of viable and non-viable adipocytes and other cellular components in aspirated fat tissue. *Plast Reconstr Surg* 122: 103-114
8. Zuk PA, Zhu M, Ashjian P, De Ugarte DA, Huang JI, Mizuno H, Alfonso ZC, Fraser JK, Benhaim P, Hedrick MH (2002) Human adipose tissue is a source of multipotent stem cells. *Mol Biol Cell* 13: 4279-4295
9. Strawford A, Antelo F, Christiansen M, Hellerstein MK (2004) Adipose tissue triglyceride turnover, de novo lipogenesis, and cell proliferation in humans measured with  $2H_2O$ . *Am J Physiol Endocrinol Metab* 286: E577-E5888
10. Spalding KL, Arner E, Westermark PO, Bernard S, Buchholz BA, Bergmann O, Blomqvist L, Hoffstedt J, Näslund E, Britton T, Concha H, Hassan M, Rydén M, Frisén J, Arner P (2008) Dynamics of fat cell turnover in humans. *Nature* 453: 783-778

11. Garcia-Olmo D, Garcia-Arranz M, Herreros D, Pascual I, Peiro C, Rodriguez-Montes JA (2005) A phase I clinical trial of the treatment of Crohn's fistula by adipose mesenchymal stem cell transplantation. *Dis Colon Rectum* 48: 1416-1423
12. Fang B, Song Y, Lin Q, Zhang Y, Cao Y, Zhao RC, Ma Y (2007) Human adipose tissue-derived mesenchymal stromal cells as salvage therapy for treatment of severe refractory acute graft-vs.-host disease in two children. *Pediatr Transplant* 11: 814-817
13. Masuda T, Furue M, Matsuda T (2004) Novel strategy for soft tissue augmentation based on transplantation of fragmented omentum and preadipocytes. *Tissue Eng* 10: 1672-1683
14. Moseley TA, Zhu M, Hedrick MH (2006) Adipose-derived stem and progenitor cells as fillers in plastic and reconstructive surgery. *Plast Reconstr Surg* 118(3 Suppl):121S-128S
15. Suga H, Eto H, Shigeura T, Inoue K, Aoi N, Kato H, Nishimura S, Manabe I, Gonda K, Yoshimura K (2008) FGF-2-induced HGF secretion by adipose-derived stromal cells inhibits post-injury fibrogenesis through a JNK-dependent mechanism. *Stem Cells*, doi:10.1634/stemcells.2008-0261
16. Kurita M, Matsumoto D, Shigeura T, Sato K, Gonda K, Harii K, Yoshimura K (2008) Influences of centrifugation on cells and tissues in liposuction aspirates: optimized centrifugation for lipotransfer and cell isolation. *Plast Reconstr Surg* 121: 1033-1041

## Legends

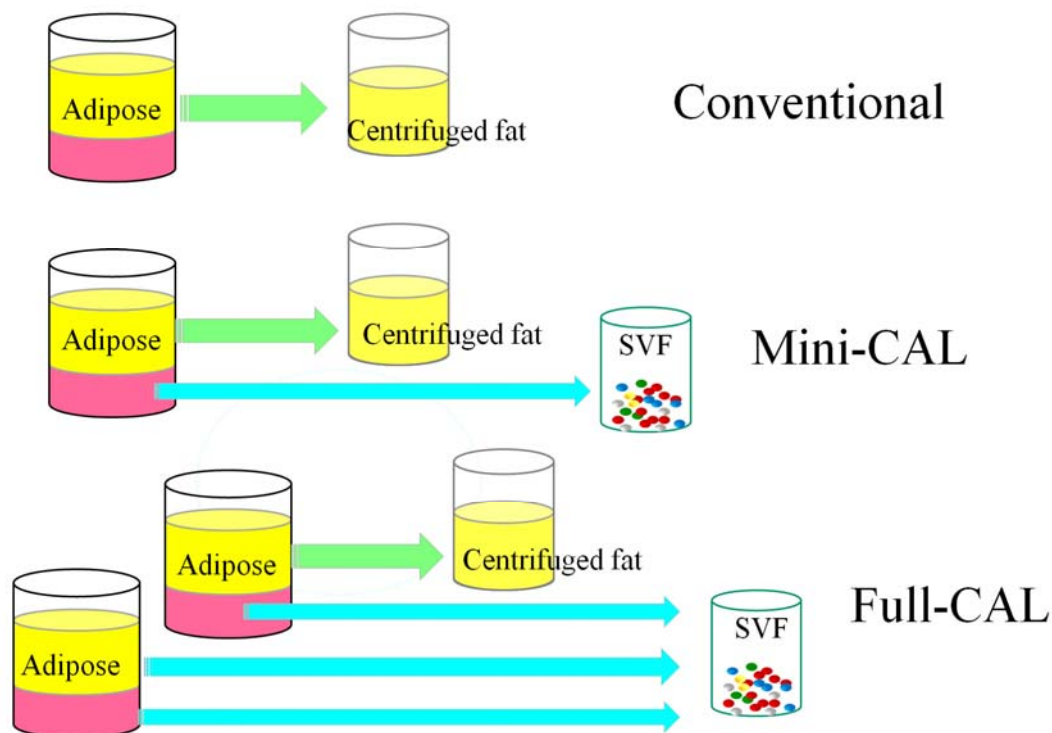


Fig. 1 Scheme of conventional lipoinjection and cell-assisted lipotransfer (CAL). The adipose portion (yellow) of liposuction aspirates is centrifuged and used as injection materials in conventional lipoinjection. In mini-CAL, the fluid portion (pink) of liposuction aspirates is used for isolation of stromal vascular fraction (SVF) containing adipose progenitor cells. In full-CAL, another volume of liposuction aspirates is additionally harvested for SVF isolation. Freshly isolated SVFs are used for supplementation of adipose progenitor cells to grafting tissues. (For the supplementation of SVF, see also Fig. 5)

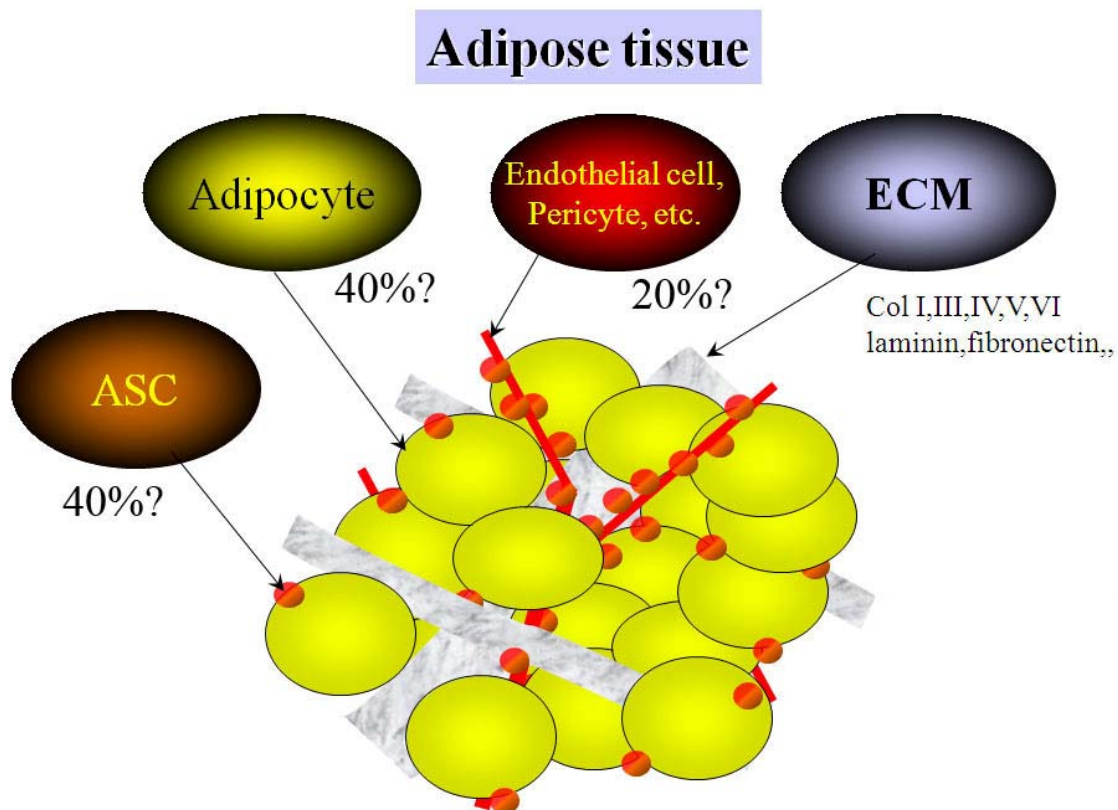


Fig. 2 Scheme of adipose tissue components. Adipocytes constitute more than 90% of tissue volume, but only less than 50% of cells in number. Adipose-derived stromal/stem cells (ASCs), endothelial cells, fibroblasts, and other cells constitute the rest of cell components. Extracellular matrix (ECM) of the adipose tissue contains some types of collagens, laminin, fibrinogen and others.

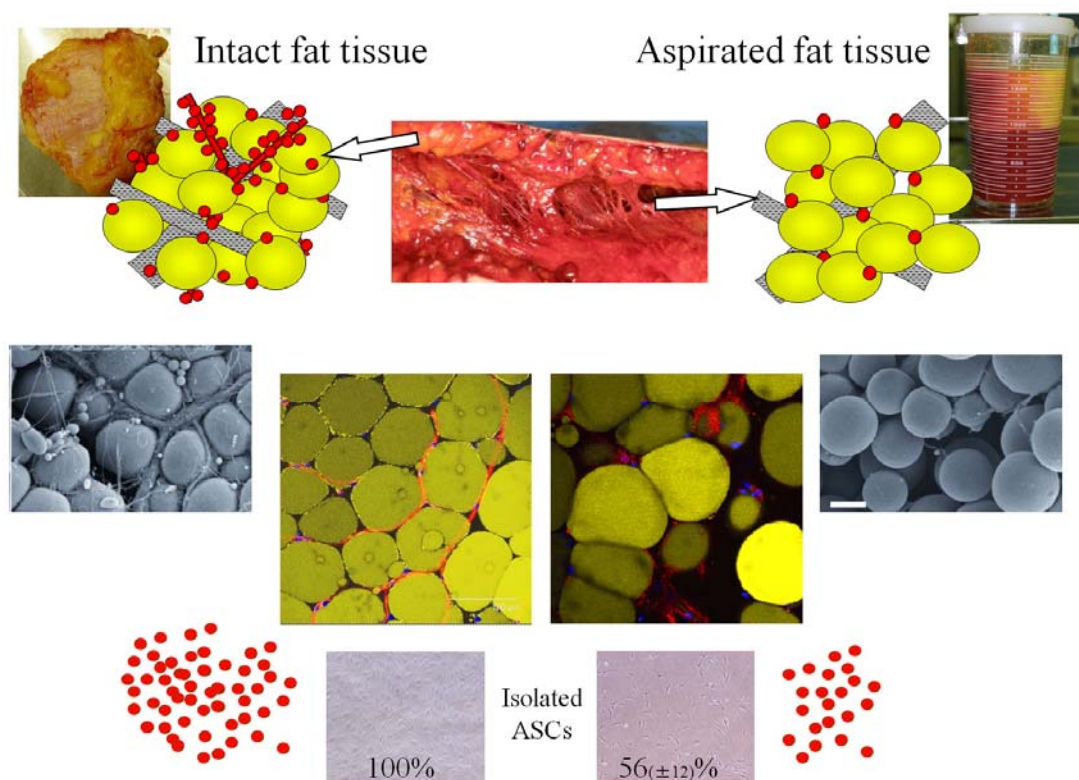


Fig. 3 Comparison of human intact fat tissue and aspirated fat tissue obtained from a single site of a single patient. Schematic views (top), electromicroscopic and whole mount staining images (middle), and isolated progenitor cells (bottom). The basic structure of adipose tissue was preserved in the aspirated fat, while vascular vessels, especially those of large size, were significantly less detected in aspirated fat compared to the excised fat. It is well known that the honeycomb structures of vascular and neural perforator networks are left intact in aspirated sites after liposuction operation. ASC yield from aspirated fat tissue was significantly less ( $56 \pm 12\%$ ) than that from excised fat tissue.



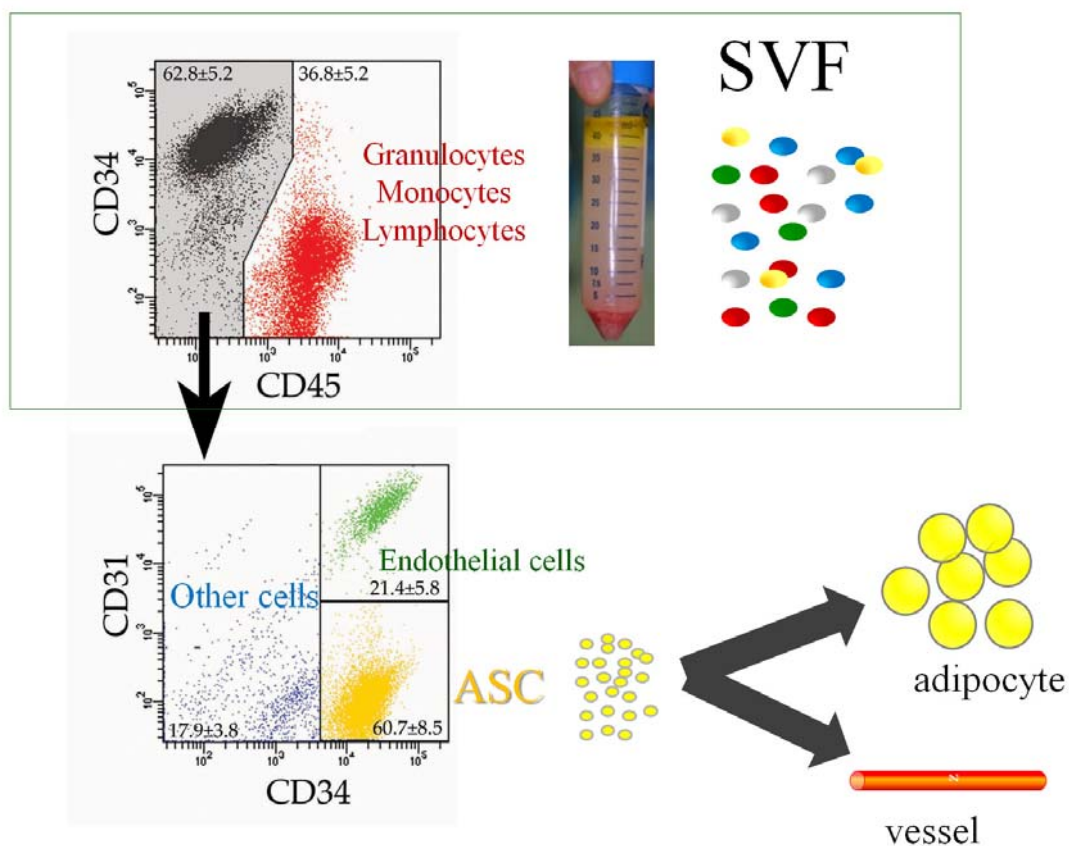


Fig. 4 Stromal vascular fraction (SVF) can be obtained from adipose and fluid portions of liposuction aspirates through collagenase digestion. SVF contains 10-40% of adipose-derived stromal cells (ASCs) (CD34<sup>+</sup>CD31<sup>-</sup>CD45<sup>-</sup>), part of which have multipotency and can differentiate experimentally into several lineages in vitro. SVF contains also blood-derived cells (CD45<sup>+</sup> cells) such as leukocytes. ASCs are considered to physiologically differentiate into adipocyte and vessels.

## Cell-Assisted Lipotransfer (CAL)

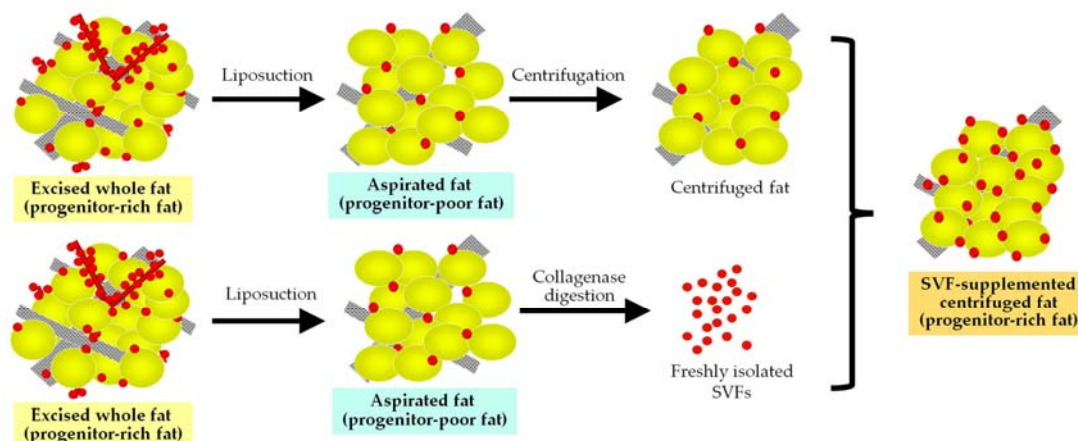


Fig. 5 Concept of cell-assisted lipotransfer (CAL). Relatively progenitor-poor aspirated fat tissue is converted to progenitor-rich fat tissue by supplementation with the stromal vascular fraction (SVF) isolated from one-half of the aspirated fat sample (Strictly speaking, the source of SVF differs between mini-CAL and full-CAL; see also Fig. 1 for the difference). SVF cells are attached to the aspirated fat tissue, which acts a scaffold in this strategy.

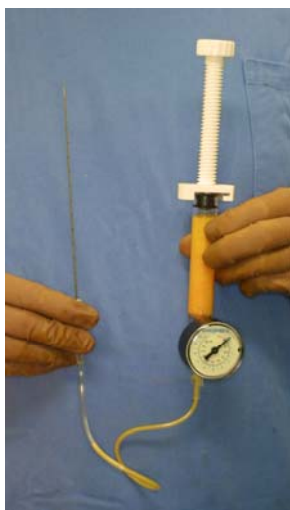


Fig. 6. Injection devices. A high-pressure injection can be performed with a disposable syringe with a threaded plunger. A 150 mm-long 16- or 18-gauge needle is connected to the syringe with a connecting tube threaded at both ends. The injection needle is rigidly manipulated by an operator, while an assistant rotates the plunger according to the operator's instruction.

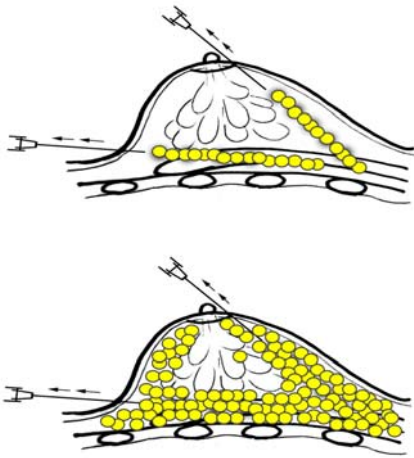


Fig. 7. Schematic instruction of the injection method. (top) The needle is inserted from either the areola margin or the infra-mammary fold in variable directions and planes to achieve a diffuse distribution. A small amount of fat tissue is injected as small aliquots or a thin string with a long needle on a syringe with a threaded plunger while the needle is continuously withdrawn. (bottom) Approximately 200-300 ml of fat tissues is usually injected for cosmetic breast augmentation on each side. Fat is not injected into the mammary glands, but into any other layers including the pectoralis muscles.

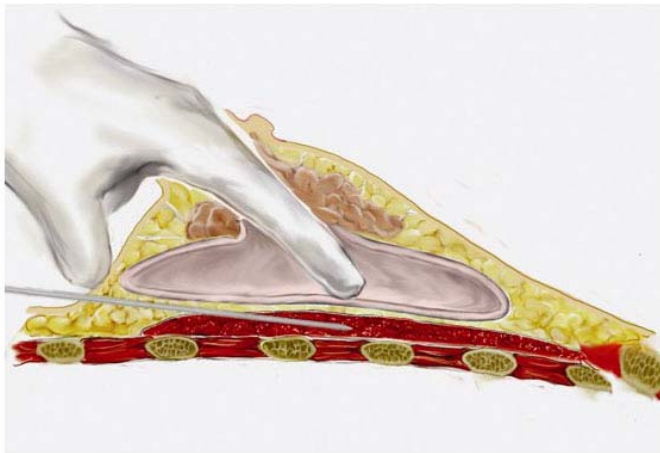


Fig. 8 Schematic illustration of the lipoinjection procedure for breast implant replacement. While injecting, operator's fingers are inserted through a periareolar skin incision into the cavity of implant capsule to determine the location of the needle tip.

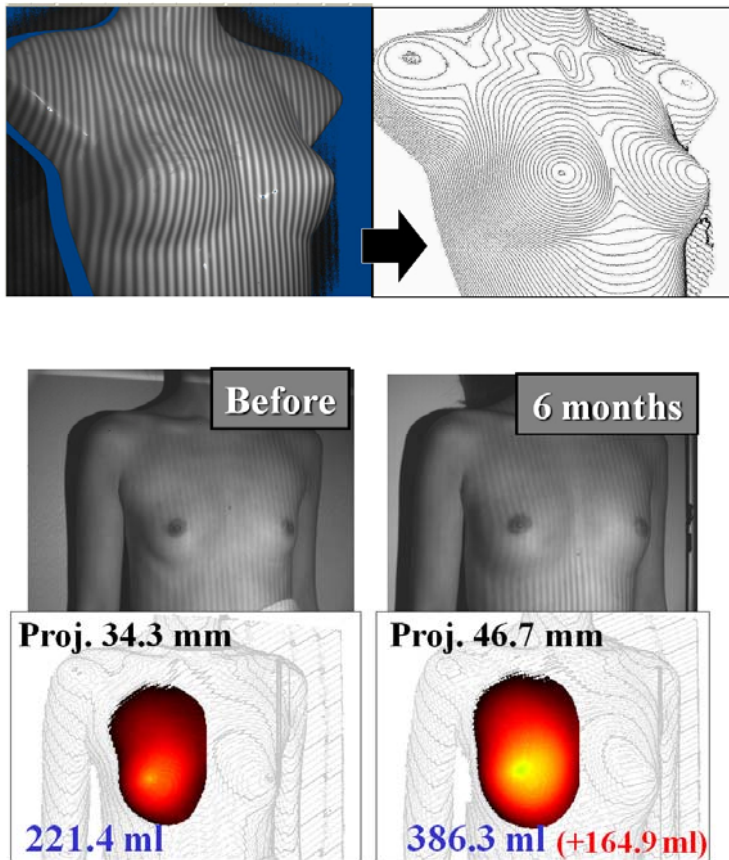


Fig. 9 Three-dimensional measurement system for breast volume. Breast volume at a sitting position can be measured by this system. Perpendicular striped lights are shown on the breasts and photographed with a stereo-type digital camera. The digital images are then analyzed with a customized software; the volume and projection of each breast above a standard plane designated by three fixed points (the shoulder, suprasternal notch, and xiphoid process) which do not usually shift after breast augmentation, are calculated.

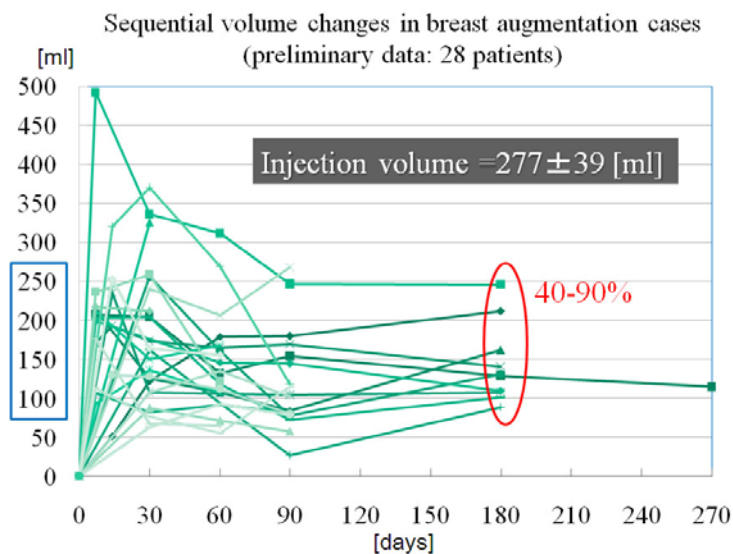


Fig. 10 Sequential volume changes after full-CAL measure by the three-dimensional measurement system (Preliminary results of 28 patients). Augmented volume varied among patients from 100 to 250 ml at 6 months, which corresponds to 40-90% survival of transplanted adipose tissue.

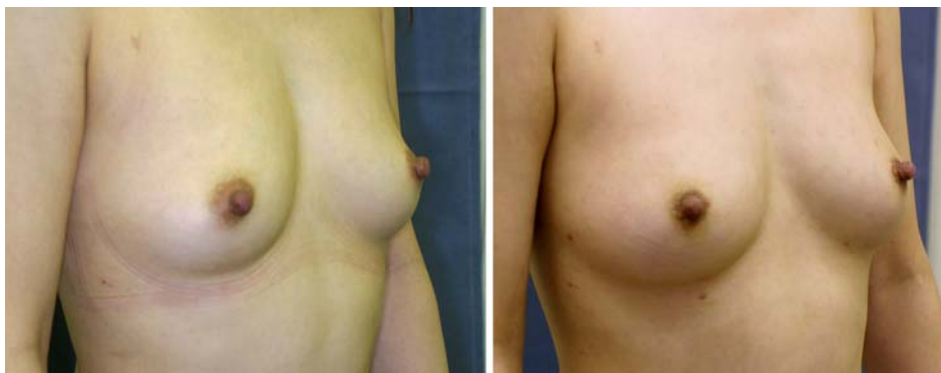

Fig. 11 Case 1 (Breast augmentation with conventional lipoinjection): Preoperative view (left) and postoperative views at 6 months (right). A 36-year-old woman underwent breast augmentation with conventional lipoinjection (280 ml in each breast). The breast mounds were soft and natural with no subcutaneous indurations, though the augmentation effect was moderate.

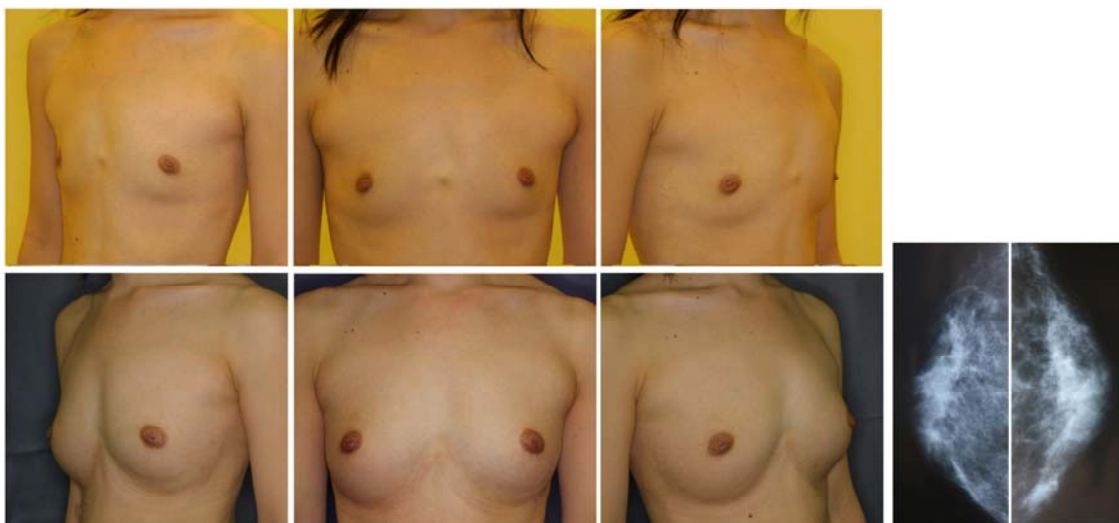


Fig. 12 Case 2 (Breast augmentation with full-CAL): A 30-year-old woman underwent breast augmentation with CAL (310 ml in each breast). Preoperative views (top) and postoperative views at 24 months (bottom). Her breasts were dramatically augmented with an increase in breast circumference difference by 8.0 cm at 24 months. The breast mounds were soft with no subcutaneous indurations. An original infra-mammary fold on the left breast is slightly visible, but injection scars are not visible. Mammograms 24 months after surgery show no abnormal signs.

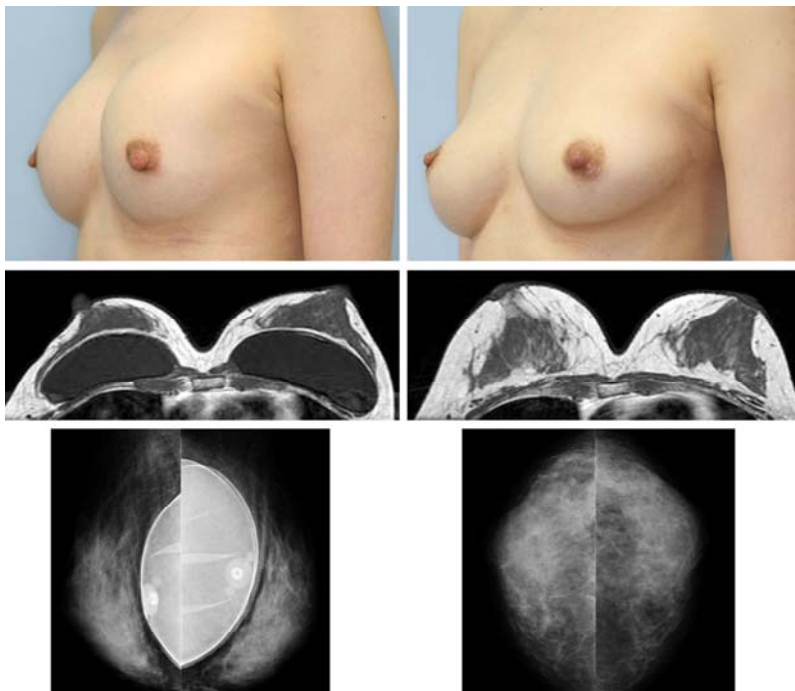


Fig. 13 Case 3 (Breast implant replacement with full-CAL): A 33-year-old woman who had 210 ml saline implants underwent implant removal and simultaneous CAL (260 ml in each breast). Preoperative (left panels) and postoperative (right panels) views at 12 months.

Clinical views showed capsular contracture and upward displacement of the left implant before surgery (top, left), while the breasts had a natural and symmetrical appearance at 12 months (top, right). T1-weighted MRI (middle, left, and right) revealed that the transplanted adipose tissue survived and formed thick layers around and under the mammary gland at 12 months. Mammograms showed that neither implant was ruptured before surgery (bottom, left) and that no calcification or other abnormal signs were visible in either breast at 12 months (bottom, right). Augmented breast mounds maintained sufficient breast volume even after implant removal, and were naturally soft without any subcutaneous indurations.

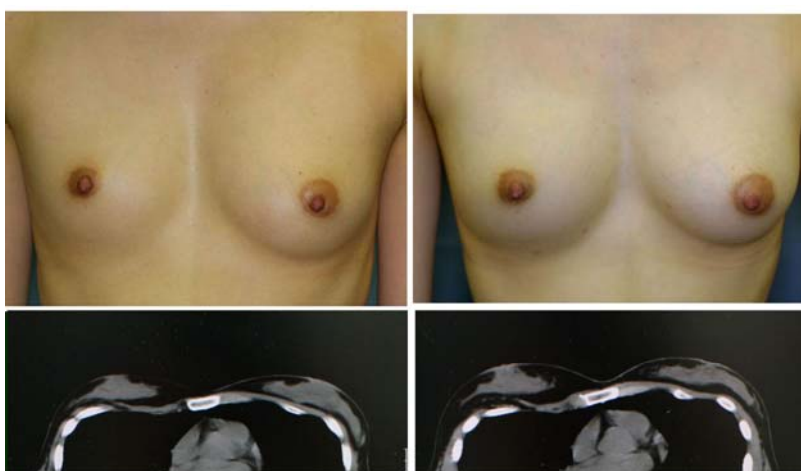


Fig. 14 Case 4 (Inborn deformity treated with full-CAL): A 26-year-old woman, who had a hypoplastic breast along with thoracic deformity on the right side, underwent CAL augmentation for both sides (325 ml and 105 ml on the right and left, respectively) Preoperative (left panels) and postoperative (right panels) views at 12 months. Both breasts were significantly improved without any indurations detected. A few small injection scars on the inframammary folds are left, but nearly invisible. Pre- and post-operative CT scans (bottom, left and right) show that adipose tissues were augmented not only subcutaneously but also under the mammary glands with no abnormal nodules or calcifications detected.

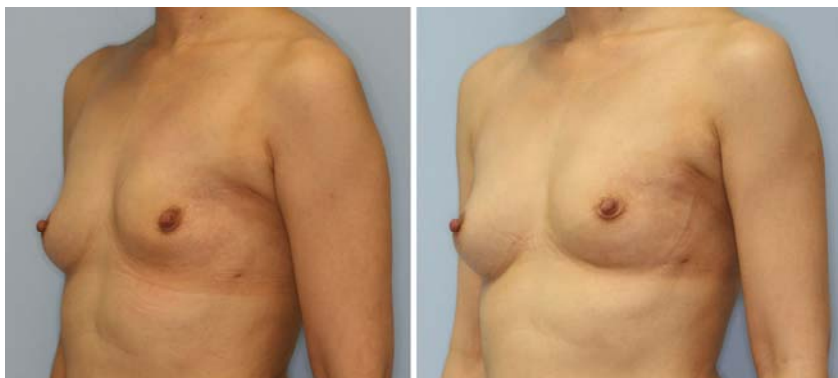


Fig. 15 Case 5 (Breast reconstruction after mastectomy with full-CAL): A 43-year-old woman, who had undergone partial mastectomy followed by irradiation therapy, underwent breast reconstruction with full-CAL (240 ml on the left side). The right healthy side was also augmented by full-CAL of 160 ml. Preoperative (left) and postoperative (right) views at 12 months. Both breasts were augmented very well, and the reconstructed breast mound was soft and showed natural skin texture.